



## Medication-Related Osteonecrosis of the Jaw – 2022 Update

Salvatore L. Ruggiero, DMD, MD, Clinical Professor, Division of Oral and Maxillofacial Surgery, Stony Brook School of Dental Medicine, Hofstra North Shore-LIJ School of Medicine, New York Center for Orthognathic and Maxillofacial Surgery, Lake Success, N.Y.

Thomas B. Dodson, DMD, MPH, Professor and Chair, University of Washington School of Dentistry, Department of Oral and Maxillofacial Surgery, Seattle, Wash.

Tara Aghaloo, DDS, MD, PhD, Professor, Oral and Maxillofacial Surgery, Assistant Dean for Clinical Research, UCLA School of Dentistry, Los Angeles, Calif.

Eric R. Carlson, DMD, MD, EdM, Professor and Kelly L. Krahwinkel Endowed Chairman, Department of Oral and Maxillofacial Surgery, University of Tennessee Graduate School of Medicine, Knoxville, Tenn.

Brent B. Ward, DDS, MD, Chalmers J. Lyons Professor of Oral and Maxillofacial Surgery, Associate Professor of Dentistry, Chair of the Department of Oral and Maxillofacial Surgery/Hospital Dentistry in the School of Dentistry and Associate Professor of Surgery for the Medical School, University of Michigan Hospital, Ann Arbor, Mich.

Deepak Kademani, DMD, MD, Chief of Staff North Memorial Health, Fellowship Director, Oral/Head and Neck Oncologic and Reconstructive Surgery Attending Surgeon, North Memorial Health and the University of Minnesota. Private practice, Minnesota Oral and Facial Surgery and Minnesota Head and Neck Surgery, Minneapolis, Minn.

### Abstract

Strategies for management of patients with, or at risk for, medication-related osteonecrosis of the jaw (MRONJ) – formerly referred to as bisphosphonate-related osteonecrosis of the jaw (BRONJ) – were set forth in the American Association of Oral and Maxillofacial Surgeons (AAOMS) position papers in 2007, 2009 and 2014. The position papers were developed by a committee appointed by the AAOMS Board of Trustees and comprising clinicians with extensive experience in caring for these patients, as well as clinical and basic science researchers. The knowledge base and experience in addressing MRONJ continues to evolve and expand, necessitating modifications and refinements to the previous position papers. Three members of the AAOMS Committee on Oral, Head, and Neck Oncologic and Reconstructive Surgery (COHNORS) and three authors of the 2014 position paper were appointed to serve as a working group to analyze the current literature and revise the guidance as indicated to reflect current knowledge in this field. This update contains revisions to diagnosis and management strategies and highlights the current research status. AAOMS maintains that it is vitally important for this information to be disseminated to other relevant healthcare professionals and organizations.

### Introduction

Medications prescribed for dental and medical conditions have potential side effects that warrant a risk-benefit discussion. Where therapeutic margins are wide and complications are readily corrected, decisions are implemented in a straightforward fashion. Where therapeutic margins are wide but complications are significant, deciding to proceed with pharmacologic treatment becomes more challenging. In most cases of MRONJ, local therapies can be successful. The fact that more complex treatment is required for a few patients should not impact decision-making for all other patients with osteonecrosis of the jaw. The medications associated with MRONJ have proven to be safe and effective in clinical trials and postmarketing analyses for most



patients and should continue as a mainstay therapy when indicated. Communicating the risks of MRONJ to patients and providers is critical to ensure appropriate medical management for the primary disease.

Undoubtedly, risk profiles may change as new medications come to market. In addition, our understanding of disease pathophysiology, risk modifiers and treatment strategies will continue to evolve. It is of the utmost importance that clinicians base their patient treatment decisions on currently available scientific evidence.

Strategies for management of patients at risk for or with MRONJ were set forth in AAOMS Position Papers in 2007,<sup>1</sup> 2009<sup>2</sup> and 2014.<sup>3</sup> These position papers were developed by a committee appointed by the AAOMS Board of Trustees and comprised of clinicians with extensive experience in caring for these patients as well as clinical and basic science researchers. The knowledge base and experience in addressing MRONJ continues to evolve and expand, necessitating modifications and refinements to the previously published position papers. A working group comprised of three members of the AAOMS Committee on Oral, Head, and Neck Oncologic and Reconstructive Surgery and three authors of the 2014 paper convened remotely in the fall of 2020 to appraise the current literature and revise the guidelines as indicated to reflect the current knowledge in this field. This update contains revisions to the pathogenesis and management strategies and highlights the current research status. AAOMS maintains it is vitally important for this information to be disseminated to other relevant healthcare professionals and organizations.

## Purpose

The purpose of this position paper is to provide updates regarding:

1. Risk estimates of developing MRONJ.
2. Comparisons of the risks and benefits of medications related to osteonecrosis of the jaw in order to facilitate medical decision-making for the treating physician, dentist, dental specialist and patient with the establishment of algorithms.
3. Guidance to clinicians regarding:
  - a. the differential diagnosis of MRONJ in patients with a history of exposure to antiresorptive medications.
  - b. MRONJ prevention measures and management strategies for patients with MRONJ based on the disease stage.

## Medications

**Bisphosphonates (BPs)** are antiresorptive medications that are effective in managing cancer-related conditions, including hypercalcemia of malignancy, spinal cord compression and pathologic fractures (skeletal-related events [SREs]) associated with bone metastases in the context of solid tumors (such as breast, prostate and lung cancers) and multiple myeloma.<sup>4, 5, 6, 7, 8, 9, 10, 11, 12, 13</sup> While the potential for BPs to improve cancer-specific survival remains controversial, these medications have had a significant positive effect on the quality of life for patients with advanced cancer involving the skeleton and reducing or preventing skeletal-related events.

Bisphosphonates also are used for the prevention of osteoporosis-related fractures (fragility fractures) in patients with osteoporosis and osteopenia.<sup>14, 15, 16</sup> BPs administered orally – including alendronate (Fosamax), risedronate (Actonel) or parenterally (zoledronic acid [Reclast]), and ibandronate (Boniva) – can result in a significant reduction in vertebral and nonvertebral fractures for patients with osteoporosis.<sup>17, 18, 19, 20</sup>

Bisphosphonate therapy also is indicated for other metabolic bone diseases such as Paget's disease of bone and osteogenesis imperfecta.<sup>21, 22, 23</sup> However, clinical trials have not demonstrated the efficacy of bisphosphonate therapy in the management of fibrous dysplasia.<sup>24</sup>

**Denosumab (DMB)**, a receptor activator of nuclear factor kappa-B ligand (RANK-L), is an antiresorptive agent that exists as a fully humanized antibody against RANK ligand and inhibits osteoclast function and associated bone resorption. When denosumab (Prolia) is administered subcutaneously every six months, there is a significant reduction in the risk of vertebral, nonvertebral and hip fractures in osteoporotic patients.<sup>25, 26, 27, 28</sup> Denosumab (Xgeva) also is effective in reducing SREs related to metastatic bone disease from solid tumors when administered monthly.<sup>29, 30, 31</sup>

RANK ligand inhibitors also have proven efficacy in the treatment of giant cell tumors of bone and fibrous dysplasia.<sup>32, 33, 34, 35, 36</sup> In contrast to BPs, RANK-L

inhibitors do not bind to bone, and their effects on bone remodeling are mostly diminished within six months of treatment cessation.

**Romozosumab** is a new monoclonal antibody used for fracture prevention in osteoporotic women. Romozosumab, administered subcutaneously, works via the Wnt pathway by binding to and inhibiting sclerostin, resulting in increased bone formation and decreased bone resorption.<sup>37</sup>

## MRONJ Case Definition

MRONJ should be distinguished from other forms of osteonecrosis (ONJ) conditions and identified by history and clinical exam. The clinical criteria required to establish a diagnosis of MRONJ have remained unchanged from the previous position paper.<sup>3</sup>

The case definition of MRONJ includes all the following elements:

1. Current or previous treatment with antiresorptive therapy alone or in combination with immune modulators or antiangiogenic medications.
2. Exposed bone or bone that can be probed through an intraoral or extraoral fistula(e) in the maxillofacial region that has persisted for more than eight weeks.
3. No history of radiation therapy to the jaws or metastatic disease to the jaws.

## Staging

A staging system for MRONJ was introduced in the 2009 AAOMS position paper and then modified in the 2014 position paper to characterize more accurately all aspects of the clinical presentation of MRONJ. Since these modifications, the AAOMS staging system has continued to be a straightforward and relevant system to properly stratify these patients. It has been adopted by several professional societies and research organizations. The staging system facilitates the creation of rational treatment guidelines and guides data collection to assess the prognosis and outcomes for MRONJ patients. While AAOMS recognizes that different classification systems are being used by other organizations,<sup>38</sup> the Association considers the AAOMS system to be a useful and widely implemented assessment tool guiding clinicians involved in the care of MRONJ patients. AAOMS remains concerned that overemphasizing variable radiographic features often attributed to MRONJ may overestimate the true disease frequency by including false positives

# Position Paper



in the numerator (e.g., cases with radiographic findings suggestive of MRONJ), but these patients do not fit the criteria for the diagnosis of MRONJ. In the orthopedic literature, the usefulness of a Stage 0 category has been established for staging avascular necrosis (AVN) of the femoral head when there is a suspicion of AVN in a patient at risk, but the diagnostic information is not conclusive.<sup>39</sup> AAOMS believes the Stage 0 category for MRONJ is analogous in principle and does account for the wide-ranging radiographic presentation of MRONJ that exists prior to overt bone exposure. Therefore, AAOMS has decided to maintain the current classification system with no modifications.

## Patients at-Risk

No apparent necrotic bone in asymptomatic patients who have been treated with IV or oral antiresorptive therapy.

## Stage 0 (Nonexposed Bone Variant)

Patients with no clinical evidence of necrotic bone but who present with nonspecific symptoms or clinical and radiographic findings, such as:

## Symptoms

- Odontalgia not explained by an odontogenic cause.
- Dull, aching bone pain in the jaw, which may radiate to the temporomandibular joint region.
- Sinus pain, which may be associated with inflammation and thickening of the maxillary sinus wall.
- Altered neurosensory function.

## Clinical Findings

- Loosening of teeth not explained by chronic periodontal disease.
- Intraoral or extraoral swelling.

## Radiographic Findings

- Alveolar bone loss or resorption not attributable to chronic periodontal disease.
- Changes to trabecular pattern sclerotic bone and no new bone in extraction sockets.



- Regions of osteosclerosis involving the alveolar bone and/or the surrounding basilar bone.
- Thickening/obscuring of periodontal ligament (thickening of the lamina dura, sclerosis and decreased size of the periodontal ligament space).<sup>40</sup>

These nonspecific findings, which characterize this variant of MRONJ without bone exposure, may occur in patients with a prior history of Stage 1, 2 or 3 disease who have been healed and have no clinical evidence of exposed bone. Progression to Stage 1 disease has been reported in up to 50 percent of patients with Stage 0 disease<sup>41</sup> and, therefore, AAOMS deems it prudent to consider Stage 0 disease as a potential precursor to MRONJ.

## Stage 1

Exposed and necrotic bone or fistula that probes to the bone in patients who are asymptomatic and have no evidence of infection/inflammation. These patients also may present with radiographic findings mentioned for Stage 0 that are localized to the alveolar bone region.

## Stage 2

Exposed and necrotic bone, or fistula that probes to the bone, with evidence of infection/inflammation. These patients are symptomatic. These patients also may present with radiographic findings mentioned for Stage 0 localized to the alveolar bone region.

## Stage 3

Exposed and necrotic bone or fistulae that probes to the bone, with evidence of infection, and one or more of the following:

- Exposed necrotic bone extending beyond the region of alveolar bone (i.e., inferior border and ramus in the mandible, maxillary sinus and zygoma in the maxilla).
- Pathologic fracture.
- Extraoral fistula.
- Oral antral/oral-nasal communication.
- Osteolysis extending to the inferior border of the mandible or sinus floor.

## Causality

It is important to understand that patients at risk for or with established MRONJ also can present with other common clinical conditions not to be confused with MRONJ. Commonly misdiagnosed conditions may include but

are not limited to alveolar osteitis, sinusitis, gingivitis/periodontitis, caries, periapical pathology, odontalgia, atypical neuralgias, fibro-osseous lesions, sarcoma, chronic sclerosing osteomyelitis, and temporomandibular joint (TMJ) disorders. It also is important to remember that delayed healing, exposed bone or sequestra (i.e., osteonecrosis [ONJ]), can occur in patients not exposed to antiresorptive agents.<sup>42</sup>

Proving causality of any medication-related complication is challenging from an epidemiologic perspective. It is well-known that MRONJ is a rare entity, multifactorial in nature, and patients with the same clinical presentation exist who have not been exposed to an antiresorptive medication. Studies have reported jaw necrosis in antiresorptive naïve patients in which necrosis was linked to bacterial, viral or fungal infections, trauma, smoking, steroids, immunocompromised host, autoimmune diseases, diabetes and chemotherapy.<sup>43, 44, 45, 46, 47, 48, 49, 50, 51, 52, 53, 54, 55, 56, 57</sup> Furthermore, patient populations – such as those with osteogenesis imperfecta – have been treated with antiresorptive agents without reports of MRONJ.<sup>58</sup> Many patients receiving medications associated with MRONJ have other comorbidities, which are likely exacerbating or contributing factors. In combination, these confounding variables make incidence and prevalence difficult to estimate.

Clinical trials, while being the gold standard for efficacy and safety data, are seldom powered to demonstrate uncommon events. Prior to the discovery of MRONJ, large randomized prospective trials of BPs with up to 10 years of patient data did not reveal any jaw bone necrosis as a complication.<sup>17, 59</sup> More recently, the HORIZON Pivotal Fracture trial tested 3,889 randomized patients given annual zoledronic acid versus placebo for three years; one patient developed MRONJ in the intervention group and one in the placebo group.<sup>18</sup> Extension of this trial for up to six years resulted in one additional MRONJ patient in the treatment group.<sup>60</sup> Extension to nine years resulted in no additional confirmed cases of MRONJ.<sup>61</sup>

Definitive causality, taken as a whole, remains a difficult task to prove in general, let alone in individual patients

presenting with clinical symptoms. Clinicians should be aware of these facts in decisions regarding treatment recommendations.

## Pathophysiology

Since the AAOMS position paper in 2014, significant knowledge has been gained regarding MRONJ pathophysiology from both clinical and particularly preclinical animal studies. It should be noted that animal studies have a number of limitations, are most often using supratherapeutic doses and likely do not truly mirror the clinical environment. That said, they are critical in understanding disease mechanisms and can serve as one reference point to evidence-based clinical decision-making.

Much debate persists among clinicians and researchers, contributing to the various treatment protocols utilized for patients today.<sup>62, 63, 64, 65</sup> Disease specificity unique to the jaws has focused leading hypotheses to include bone remodeling inhibition, inflammation or infection, angiogenesis inhibition, innate or acquired immune dysfunction, as well as genetic predisposition.<sup>3, 65</sup> Both animal and human studies suggest that an antiresorptive medication, coupled with inflammation or infection, is necessary and sufficient to induce MRONJ. However, as more knowledge is gained on the subject, it is becoming increasingly apparent that MRONJ is multifactorial, and it is likely that multiple hypotheses can explain the overall pathophysiology of this disease.<sup>3, 65</sup>

## Bone Remodeling Inhibition

The definition of MRONJ includes oral or parenteral administration of antiresorptive medications, such that bone remodeling suppression is a central hypothesis in its pathophysiology. Antiresorptive medications, including BPs and denosumab (DMB), have direct effects on osteoclast formation, differentiation or function. In osteoporosis, BPs are a first-line therapy to decrease bone remodeling, increase bone mineral density, and decrease vertebral and long bone fractures.<sup>66, 67</sup> BPs, in higher doses, also are utilized in primary bone malignancy and bone metastases to decrease SREs, including hypercalcemia of malignancy, reduce severe bone pain and improve quality of life.<sup>68, 69, 70, 71, 72</sup> Although DMB has only been approved for use since 2010, its use has increased significantly for both osteoporosis and malignancy in the last decade. Prevalence of MRONJ with DMB users is at least as high as BP users, likely due to its increased potency to inhibit bone resorption.<sup>30, 73, 74, 75</sup> This is supported in the jaws as animal studies demonstrate

# Position Paper



absent osteoclasts around the alveolar bone of DMB-treated mice.<sup>76</sup> Human bone specimens also show an increased number of nonfunctional osteoclasts surrounding necrotic bone in BP-treated patients,<sup>77</sup> further reinforcing bone remodeling inhibition as a leading hypothesis in MRONJ pathophysiology. With the appearance of MRONJ in DMB-treated patients, it becomes increasingly apparent that the underlying pathophysiology involves dysfunctional osteoclasts.

Animal studies evaluating withdrawal of BPs or DMB further highlight the importance of bone remodeling in MRONJ prevention and resolution. Rodents with established ONJ failed to resolve when antiresorptives were withdrawn. However, discontinuing DMB, but not BPs, prior to tooth extraction successfully prevented MRONJ development in rats.<sup>78, 79</sup> Moreover, parathyroid hormone, which acts directly on osteoblasts to induce bone formation and indirectly increases osteoclastic bone resorption and overall remodeling, has been shown to prevent MRONJ and improve extraction socket healing in rodents and preliminarily in patients.<sup>80, 81, 82</sup> This observation provides further support for the central role of osteoclast inhibition in MRONJ pathogenesis.

## Inflammation or Infection

Although most studies report tooth extraction as the major inciting event for MRONJ development, it is clear that most extracted teeth had pre-existing periodontal or periapical disease.<sup>3, 64, 83, 84</sup> From this patient information, animal models of inflammation or infection were developed to replicate clinical, radiographic and histologic features of MRONJ.<sup>85, 86, 87, 88</sup> Presence of inflammatory cytokines, specifically at the site of MRONJ, also support the strong role of inflammation.<sup>89</sup> As evidence of increased systemic inflammation and its contribution to MRONJ development, mice with experimentally induced rheumatoid arthritis demonstrated more severe MRONJ with increased oral bone exposure, more pronounced radiographic features, intense local inflammatory infiltrate and larger areas of histologic necrosis.<sup>90</sup> Further support for the inflammatory etiology showed that removal of the inflammatory nidus in ligature-induced periodontitis ameliorated MRONJ development in mice, demonstrating



reduced inflammation and prevention of disease progression.<sup>91</sup> Moreover, transplantation of peripheral blood mononuclear cells with anti-inflammatory properties reduced MRONJ prevalence by improving soft-tissue healing, decreasing inflammatory polymorphonuclear cells and inflammatory marker expression, as well as enhancing vascularity.<sup>92</sup> These preclinical findings confirm the irrefutable role of inflammation or infection in MRONJ disease prevalence, severity and resolution.

The presence of bacteria on the exposed necrotic bone also contributes to disease severity, where pain and signs of infection define Stage 2 MRONJ.<sup>3, 93, 94</sup> This is not surprising since poor oral hygiene and biofilm presence are associated with MRONJ development,<sup>95, 96</sup> and oral health maintenance and dental prophylaxis before initiating antiresorptive therapy can decrease MRONJ prevalence.<sup>97, 98</sup> Importantly, clinical treatment protocols to reduce the biofilm and eradicate infection have emerged as important alternatives to debridement and resection in patients who may not be ideal surgical candidates.<sup>63</sup>

## Angiogenesis Inhibition

Osteonecrosis is traditionally defined as avascular necrosis or aseptic necrosis, most commonly characterized as osteocyte death after decreased blood flow to the femoral head.<sup>99</sup> However, MRONJ is defined as necrotic bone in the maxillofacial region after exposure to either antiresorptive or antiangiogenic medications.<sup>3</sup> BPs such as zoledronic acid directly inhibit angiogenesis *in vitro* and *in vivo*<sup>100, 101, 102, 103</sup> and animal models demonstrate decreased vascularity in sites of MRONJ and decreased microvessel numbers during early stages of bone healing.<sup>104</sup> In addition, angiogenesis normally seen during extraction socket healing is inhibited by BPs, and both BPs and DMB have been shown to decrease arterial area, venous area and overall vascularity of periodontal tissues during early and late MRONJ development.<sup>105, 106</sup> Importantly, antiangiogenic medications, such as Vascular Endothelial Growth Factor (VEGF) inhibitors, tyrosine kinase receptor inhibitors and immunomodulatory drugs,<sup>107, 108, 109</sup> can be associated with MRONJ. Moreover, patients with multiple myeloma receiving both antiresorptive and antiangiogenic medications, as shown in several studies,<sup>110, 111, 112, 113, 114</sup> have a higher MRONJ prevalence. Important aspects of MRONJ treatment include determining disease margins, which can be challenging as microvascular mucosal abnormalities can be seen adjacent to frank MRONJ lesions.<sup>115</sup> It is important to note that the incidence of MRONJ in patients on antiangiogenics is much lower than those taking antiresorptive medications.

## Innate or Acquired Immune Dysfunction

Although animal studies confirm that an antiresorptive medication—coupled with inflammation or infection—is necessary and sufficient to produce MRONJ, not all patients with dental infections develop the disease. It is well-known that patients with medical comorbidities such as diabetes or rheumatoid arthritis or immunocompromised states are at significantly higher risk for MRONJ with or without exposure to antiresorptive agents.<sup>3, 64, 114, 116</sup> Patients with metastatic or primary bone malignancies have a compromised immune system.<sup>117</sup> This also has been confirmed with animal studies, where chemotherapy, steroids and disease-modifying antirheumatic drugs (DMARDs), combined with antiangiogenic medications and an antiresorptive, increase MRONJ severity or prevalence.<sup>118, 119, 120</sup> Moreover, higher rates of MRONJ occur in patients with multiple myeloma who receive multiple chemotherapeutic agents.<sup>110, 121</sup>

Replenishing the area of nonhealing MRONJ lesions with mesenchymal stem cells (MSCs) to overcome immune dysfunction is a potential area of therapeutic interest, especially in patients who are immunocompromised. A recent study showed altered numbers and patterns of T-cells in human and rat MRONJ necrotic bone samples as compared to healthy patients and non-MRONJ sites.<sup>122</sup> Preclinical studies also demonstrate healing or prevention of MRONJ lesions after systemic infusion with adipose or bone marrow-derived MSCs.<sup>123, 124, 125</sup>

## Genetic Factors

In the 2014 paper, the authors identified several reports describing single-nucleotide polymorphisms (SNPs) that were associated with the development of MRONJ. Most of these SNPs were located within regions of the gene associated with either bone turnover, collagen formation or certain metabolic bone diseases. Indeed, increasing evidence is available to support the role of SNPs with MRONJ.<sup>126, 127</sup> Specific links to sirtuin-1 (SIRT1), a bone remodeling regulator that promotes bone formation, may be protective against MRONJ if upregulated.<sup>128</sup> SIRT1 also is involved in both reduction of inflammation and induction of angiogenesis, suggesting a role in several



of the leading MRONJ hypotheses.<sup>128</sup> Other genes also have been reported to increase MRONJ risk through their role in angiogenesis, bone remodeling and immune responses, including PPAR gamma, CYP2C8 and many others.<sup>129</sup> Collectively, these studies suggest that MRONJ is a multifactorial disease and that genetic factors may play a role in its development.<sup>130</sup> Overall, however, current studies document either a weak or no association between genetic factors measured and risk for MRONJ.<sup>131</sup> To determine predisposition, studies with larger sample sizes should be performed, with genetic risks confirmed in both BPs and DMB-treated patients who have breast or prostate cancer metastases, multiple myeloma or osteoporosis.

## Risk factors for MRONJ

### Medication-related Risk Factors

To estimate the risk for medications associated with MRONJ, the primary parameter to be considered is the therapeutic indication for treatment (e.g., malignancy or osteoporosis/osteopenia). The data suggest that antiresorptive medications (i.e., BPs and DMB) are associated with an increased risk for developing MRONJ. The risk of MRONJ is considerably higher in the malignancy group (<5%) than in the osteoporosis group (<0.05%). Current data are insufficient to identify other medications as risk factors for developing MRONJ.

### MRONJ risk among cancer patients

For estimating the risk for MRONJ among patients exposed to a medication, the risk for MRONJ in patients not exposed to antiresorptive medications must be estimated (Table 1). The risk for MRONJ among cancer patients enrolled in clinical trials and assigned to placebo groups ranges from 0 percent to 0.7 percent.<sup>132, 133, 134, 135, 136, 137, 138</sup>

- a. Among cancer patients exposed to zoledronate, the cumulative risk of MRONJ clusters in the low single digits, <5 percent, and ranges from 0 percent to 18 percent.<sup>113,132,133,137, 138, 139, 140, 141, 142, 143, 144</sup> The wide variation in estimates may be explained by the varying durations of follow-up, one to 10 years, reported in the various studies. The risk of MRONJ among cancer patients exposed to zoledronate ranges between 2-10 times higher than cancer patients treated with placebo.
- b. Among cancer patients exposed to DMB, the risk of MRONJ ranges from 0 percent to 6.9 percent, with most studies reporting rates <5 percent.<sup>113,134,135,138,141,142,144,145</sup> The risk for MRONJ

among cancer patients exposed to DMB is comparable to the risk of MRONJ in cancer patients exposed to zoledronate.<sup>135,141,142,144,145</sup>

Since the 2014 update, investigators have implicated numerous families of medications as risk factors for MRONJ.<sup>146, 147, 148, 149</sup> These medications include tyrosine kinase inhibitors (TKIs) such as sunitinib, monoclonal antibodies (bevacizumab), fusion proteins (afibercept), mTOR inhibitors (everolimus), radiopharmaceuticals (radium 223), selective estrogen receptor modulators (raloxifene) and immunosuppressants (methotrexate and corticosteroids).

When compared to antiresorptive medications, the level of evidence supporting other medication families as risk factors for MRONJ is level 5 (e.g., isolated case reports or mini-case series [<5 cases]).<sup>146, 147, 148, 149</sup> Given that the poly-pharmaceutical management of cancer patients combined with the fact that cancer and immunosuppression are risk factors for MRONJ without exposure to antiresorptive agents, AAOMS believes that identifying a single medication as being the etiologic agent for MRONJ seems unlikely in case reports or mini-case series. Further controlled prospective studies will be required to measure the risk of MRONJ associated with non-antiresorptive agents.

### MRONJ Risk Among Osteoporosis Patients

Most dentists and oral and maxillofacial surgeons evaluate patients in their practices exposed to antiresorptive therapy for management of osteoporosis (Table 1).

- a. Risk for MRONJ among osteoporotic patients exposed to BPs.

The risk of MRONJ among study subjects assigned to placebo groups enrolled in osteoporosis clinical trials ranged from 0 percent to 0.02 percent.<sup>26,150,151</sup> Among study subjects treated with BPs, the risk of MRONJ is 0.02 percent to 0.05 percent.<sup>37,75,152</sup> Among patients exposed to IV zoledronate, the risk for MRONJ is estimated to be  $\leq 0.02\%$  ( $\leq 2$  per 10,000). For patients exposed to oral bisphosphonates, MRONJ risk is estimated to be  $\leq 0.05\%$  ( $\leq 5$  per 10,000).



- b. MRONJ risk among osteoporotic patients exposed to RANK-L inhibitors.

After 10 years of follow-up, among patients exposed to DMB, the risk for MRONJ was reported to be 0.3 percent, almost an order of magnitude higher than for BPs.<sup>153</sup>

- c. The risk for MRONJ when exposed to romosozumab (0.03 percent to 0.05 percent) is comparable to alendronate (0.05 percent).<sup>37,151</sup> In the placebo group, there were no cases of MRONJ.<sup>151</sup> It will be important to continue to monitor romosozumab to assess its role as a risk factor for MRONJ.

The risk for MRONJ among osteoporosis patients treated with BPs ranges from 0.02 percent to 0.05 percent and overlaps the risk for MRONJ of patients enrolled in placebo groups (0 percent to 0.02 percent). The risk for MRONJ among patients treated with denosumab, however, has a larger range—from 0.04 percent to 0.3 percent. As such, additional research will be needed to better estimate the risk of MRONJ among patients receiving denosumab. The risk of MRONJ for patients exposed to romosozumab (0.03 percent to 0.05 percent) more closely aligns with the risk associated with BPs.<sup>37,151</sup> However, given its recent introduction as a therapeutic agent, additional research will be needed to refine its association and risk estimate for MRONJ.

Based on this current review of data, the risk of developing MRONJ among osteoporotic patients exposed to BPs, DMB and romosozumab is low. The occurrence of cases seen is best explained by a rare event among a large number of patients, 5.1 million over the age of 55, exposed to these drugs.<sup>154</sup>

## MRONJ Risk Among Patients with Nonmalignant Bone Disease

- a. AAOMS identified two studies where DMB was used to manage aggressive giant cell tumors of bone.<sup>155, 156</sup> The risk of developing MRONJ in the two studies was broad and ranged from 0.7 percent to 5 percent. This is comparable to the risks of developing MRONJ in subjects treated with DMB for malignancies (range = 0 percent to 6.9 percent). Additional studies will be needed to confirm the risk estimate for MRONJ among patients with nonmalignant bone disease treated with antiresorptives.

- b. There are very limited data describing the occurrence of MRONJ in the pediatric population for osteogenesis imperfecta and other conditions. In a systematic review estimating the risk of MRONJ among children with osteogenesis imperfecta, there were no cases of MRONJ identified in a sample of 486 subjects treated for 4.5 to 6.8 years.<sup>157</sup> In a different systematic review that estimated the risk for MRONJ among those under the age of 24 for several conditions treated using BPs, no cases of MRONJ were reported.<sup>158</sup> The overall quality of the studies included in both systematic reviews was limited by small sample sizes or lack of MRONJ-related risk factors.

## Duration of Medication Therapy as a Risk Factor for MRONJ

Regardless of indications for therapy, the duration of antiresorptive therapy is a risk factor for developing MRONJ. Among cancer patients exposed to zoledronate or DMB (n = 5,723), the risk of developing MRONJ was, respectively, 0.5 percent and 0.8 percent at 1 year, 1.0 percent and 1.8 percent at 2 years, and 1.3 percent and 1.8 percent at 3 years.<sup>141</sup> In a study by Saad et al., the investigators combined three-blinded phase 3 trials and found similar results, including a plateau after two years for patients exposed to DMB.<sup>5</sup> In a more recent systematic review by Ng et al., the risk of MRONJ among cancer patients treated with zoledronate, was 1.6 percent to 4 percent after two years of treatment and 3.8 percent to 18 percent with more than two years of treatment.<sup>145</sup> Likewise, for DMB, the risks for developing MRONJ were 1.9 percent and 6.9 percent with <24 months and >24 months of exposure, respectively.<sup>145</sup>

For patients receiving bisphosphonate therapy to manage osteoporosis, data regarding duration are mixed. Early on, the prevalence of MRONJ was reported as increasing over time from near 0 percent at baseline to 0.21 percent after four or more years of BP exposure based on retrospective analysis.<sup>152,159</sup> More recent data from a large prospective, randomized placebo controlled trial demonstrate no significant increase in MRONJ in patients treated for up to nine years.<sup>18,60,61</sup> In addition, there are no postmarketing





data or general clinical experience to support an MRONJ prevalence of 0.21 percent in any osteoporosis-treated group. Therefore, while duration may be a risk factor, the overall risk remains low.

## Local Factors

### Dentoalveolar Operations

Dentoalveolar operations are the most common identifiable predisposing factor for developing MRONJ. Several studies report that among patients with MRONJ, tooth extraction is cited as a predisposing event ranging from 62 percent to 82 percent.<sup>5,75,160</sup> While this information is important, it is not what most patients or clinicians want to know. Most providers and patients want an answer to the following clinical question: “Among patients exposed to antiresorptive medications, what is the risk for developing MRONJ following tooth extraction (or other dentoalveolar procedures such as implant placement or periodontal procedures)?” Current estimates for the risk of MRONJ among osteoporotic patients exposed to BPs following tooth extraction range from 0 percent to 0.15 percent.<sup>161,162</sup> For osteoporotic patients exposed to DMB, the risk for MRONJ following tooth extraction was 1 percent.<sup>163</sup>

For cancer patients exposed to BPs, the risk of developing MRONJ after tooth extraction ranges from 1.6 percent to 14.8 percent.<sup>164, 165, 166</sup> In a small case series,  $n = 61$  subjects having 102 extractions, the risk for MRONJ after tooth extraction was 13.1 percent.<sup>167</sup> In a systematic review by Gaudin et al., the risk for MRONJ after tooth extraction ( $n = 564$ ) was estimated to be 3.2 percent.<sup>162</sup> While the estimates for developing MRONJ in high-risk patients undergoing tooth extraction vary, they cluster between 1 percent and 5 percent, similar to estimates of osteoradionecrosis following tooth extraction in irradiated patients.

The risk of developing MRONJ among patients who have been exposed to antiresorptive medications for other dentoalveolar operations such as dental implant placement and endodontic or periodontal procedures is unknown.<sup>168</sup> The risk for MRONJ after implant placement among patients treated with DMB has been reported to be 0.5 percent.<sup>163</sup> Absent better data, AAOMS cautions the use of these procedures in cancer patients exposed to antiresorptive therapies and recommends osteoporosis patients be informed of potential risks, albeit low, including development of MRONJ, early and late implant failure all of which have been described in case reports and clinical trials.

### Anatomic Factors

Limited new information regarding anatomic risk factors for MRONJ is available. MRONJ is more likely to appear in the mandible (75 percent) than the maxilla (25 percent) but can appear in both jaws (4.5 percent).<sup>5,75</sup> Denture use was associated with an increased risk for MRONJ among cancer patients exposed to zoledronate (OR = 4.9; 95 percent CI = 1.2 to 20.1).<sup>169</sup> In a study by Vahtsevanos et al., using a sample of 1,621 cancer patients treated with intravenous zoledronate, ibandronate or pamidronate, there was a twofold increased risk for MRONJ among denture wearers.<sup>170</sup>

### Concomitant Oral Disease

Preexisting inflammatory dental disease such as periodontal disease or periapical pathology is cited as a risk factor.<sup>75,168</sup> Among cancer patients with MRONJ, the preexisting inflammatory dental disease was a risk factor among 50 percent of the cases.<sup>5,165</sup>

Given that a common treatment of inflammatory dental disease is tooth extraction, pre-existing dental disease may confound the relationship between tooth extraction and risk for MRONJ. Tooth extraction may expose MRONJ as opposed to being the precipitating event. It would be valuable to see an estimate of the association between tooth extraction and MRONJ adjusted for pre-existing inflammatory dental disease.

After tooth extraction and periodontal disease, the next most common risk factor is reported as “spontaneous” MRONJ with no identifiable dental risk factor.<sup>168</sup>

### Demographic and Systemic Factors and Other Medications

Age and sex are variably reported as risk factors for MRONJ.<sup>5, 165, 169, 170, 171</sup> The higher prevalence of MRONJ in the female population is likely a reflection of the underlying disease for which the agents are being prescribed (e.g., osteoporosis, breast cancer).

As noted previously, those under the age of 24 treated with antiresorptives for benign bone diseases have not demonstrated any risk for MRONJ even after an extended



duration of therapy. The overall quality of the studies included even in systematic reviews is based on small sample sizes and the lack of other MRONJ-related risk factors. The risk of developing MRONJ in the pediatric population requires continued surveillance.

Corticosteroids are associated with an increased risk for MRONJ.<sup>5,168,171</sup> There are concerns that corticosteroids increase the risk for MRONJ when given in conjunction with antiresorptive agents.

Comorbid conditions are inconsistently reported to be associated with an increased risk for MRONJ, including anemia (hemoglobin < 10 g/dL) and diabetes.<sup>5,171</sup> Cancer type also is variably reported as a risk factor.<sup>170,172</sup>

Tobacco use is variably reported as a risk factor for MRONJ. In a case-control study, tobacco use approached statistical significance as a risk factor for MRONJ in cancer patients (OR = 3.0; 95 percent CI = 0.8 to 10.4).<sup>169</sup> In a more recent case-controlled study, tobacco use was not associated with ONJ in a sample of cancer patients exposed to zoledronate.<sup>171</sup> Vahtsevanos did not report an association between tobacco use and MRONJ.<sup>170</sup>

In brief, after chemotherapy and corticosteroid exposure, the next most reported comorbidity is “no comorbidity.”<sup>168</sup>

In summary, the current literature reaffirms that the risk of MRONJ is significantly greater in cancer patients receiving antiresorptive therapy compared to patients receiving antiresorptive therapy for osteoporosis. Moreover, the risk of MRONJ in osteoporosis patients receiving antiresorptive therapy continues to be very low regardless of drug type (BPs, DMB, romoszumab) or dosing schedule.

## Management Strategies

### Treatment Goals

The major goals of treatment for patients at risk of developing or who have established MRONJ are:

- Prevention of MRONJ (see section MRONJ risk among cancer patients below).
- Prioritization and support of continued oncologic treatment in patients receiving antiresorptive therapy alone or in combination with immune modulators or antiangiogenic medications:
  - Oncology patients benefit from the therapeutic effect of antiresorptive therapy by controlling bone pain and reducing the incidence of other SREs.

- Prioritization and support of continued bone health and the prevention of fragility fractures:
  - Patients with osteoporosis, osteopenia and other metabolic bone diseases benefit from antiresorptive therapy by significantly reducing the risk of fragility fractures and other skeletal-related events.
- Preservation of quality of life through:
  - Patient education and reassurance.
  - Control of pain.
  - Control of secondary infection.
  - Prevention of extension of lesion and development of new areas of necrosis.

### Prevention of MRONJ

Numerous studies demonstrate potentially modifiable factors for reducing the risk of MRONJ, including performing high-risk surgical procedures prior to initiating therapy,<sup>95,173, 174, 175</sup> using preoperative and postoperative antibiotics and antimicrobial mouth rinses,<sup>174,176, 177, 178, 179, 180</sup> primarily closing extractions sites,<sup>176, 177, 178</sup> and maintaining good oral hygiene.<sup>95,166,176,177,181</sup> Maximizing overall patient health is always indicated, such as smoking cessation and diabetes optimization. Although no individual strategy nor collection of strategies eliminates all MRONJ risks, these preventive procedures are recommended.

The prevention of MRONJ begins with the realization that patients receiving antiresorptive therapies may have altered osseous wound-healing capacity, which may also be a risk for developing MRONJ. Similar to other common preventive strategies in medicine and dentistry, healthcare providers need to recognize the importance of coordinated dental care and pretreatment management in minimizing the risk of MRONJ. This requires a continuous effort to educate patients, dentists and medical professionals about the real risks associated with these therapies and clinical prevention paradigms that can mitigate MRONJ development.

AAOMS re-emphasizes the importance of a multidisciplinary approach to the treatment of patients who are receiving antiresorptive therapies. This may also

apply to other immune modulators or targeted therapies taken alone or in combination with antiresorptives. This approach includes consultation with an appropriate dental professional when it is determined a patient would benefit from these therapies.

## Optimization of Oral Health

The 2014 AAOMS position paper identified valid prophylactic treatment strategies that reduce the incidence of MRONJ. The efficacies of these strategies remain validated by subsequent studies that demonstrate the importance of pretreatment dental screening and regimented dental surveillance. There is a robust level of support for early screening and initiation of appropriate dental care prior to the initiation of antiresorptive therapy.<sup>38,182, 183, 184, 185, 186</sup>

These preventive management strategies not only decrease the risk for MRONJ but accrue the benefits that all patients enjoy with optimum oral health.<sup>186, 187, 188, 189, 190, 191, 192, 193</sup>

In a prospective study of prostate cancer patients with bone metastasis, instituting a more regimented dental health surveillance system resulted in a 2.5-fold reduction in relative risk compared to symptomatically driven dental treatment.<sup>186</sup> In a systematic review aimed at identifying prevention strategies associated with tooth extractions in patients at risk for MRONJ, no randomized clinical trials were reported.<sup>194</sup> However, there are many animal studies that demonstrate that periodontal or periapical inflammation plays a key role in creating a local environment that supports the development of bone necrosis in the context of systemic antiresorptive therapy.<sup>85,91,195,196</sup>

Treatment planning for patients at risk of developing MRONJ should include a thorough examination of the oral cavity and a radiographic assessment when indicated. It is important to identify both acute infection and sites of potential infection to prevent future sequelae that could be exacerbated once drug therapies begin. Considerations during the clinical and radiographic assessment include patient motivation, patient education regarding dental care, fluoride application, chlorhexidine rinses, tooth mobility, periodontal disease, presence of root fragments, caries, periapical pathology, edentulism and denture stability.<sup>197</sup>

An additional benefit of early dental consultation, when the use of antiresorptive therapy is being considered, is that the patient is informed of the risk associated with these drug therapies and the risk incurred by not undergoing recommended dental preventive measures before consenting to treatment.

## Cessation of At-Risk Medication Therapy (Drug Holiday) Prior to Tooth Extraction or Other Procedures that Involve Osseous Injury (e.g., Dental Implant Placement, Periodontal or Apical Endodontic Treatment)

The clinical practice of antiresorptive drug holidays to mitigate MRONJ risk in patients undergoing dentoalveolar surgery was controversial at the time of the previous AAOMS position paper in 2014 and remained the case in 2021. While the practice of a drug holiday has been accepted and recommended by several international professional societies,<sup>3,38,182,183,198</sup> the evidence to support or refute such positions remains inconclusive. The difficulty in establishing or refuting the efficacy of drug holidays is due to the rarity of MRONJ in these patient populations. Therefore, since few events are reported, randomized-controlled trials provide insufficient data to create sound treatment protocols. In a 2020 systematic review that studied the efficacy of antiresorptive drug holiday in preventing MRONJ, a variety of papers were identified with differing conclusions suggesting that a high level of evidence for supporting or refuting the use of a holiday is missing.<sup>199</sup>

The historical use of a drug holiday was intended to decrease the prevalence of MRONJ subsequent to the performance of high-risk surgical procedures. The concern regarding this practice is the loss of efficacy of antiresorptive therapy with the development of SREs and fragility fractures. Among others, factors for consideration may include disease-related risk (cancer vs. osteoporosis), drug-dosing frequency, duration of therapy, comorbidities, other medications (especially chemotherapy, steroids or antiangiogenics), degree of underlying infection/inflammation and extent of surgery to be performed.

Of note, the working group was unable to reach a consensus regarding a recommendation on drug holidays and was evenly split between offering drug holidays to patients on a case-by-case basis using prior recommendations and those who never recommend drug holidays, believing that the risks of potential deleterious effects of suspending antiresorptive therapy may outweigh a benefit.



A special concern should be considered for suspending RANKL inhibitors in osteoporosis patients. Several studies have demonstrated a rebound increase in bone resorption following the discontinuation of DMB, resulting in an increased risk of multilevel vertebral fractures.<sup>200, 201, 202</sup> If DMB is to be suspended, the timing and duration of the holiday should be optimized in order to minimize this risk. The planned dentoalveolar surgery can be completed 3-4 months following the last dose of DMB when the level of osteoclast inhibition is waning. It can then be reinstated 6-8 weeks postsurgery. This management strategy minimizes the length of the drug holiday while maintaining a favorable environment for bone healing.

## **Bone Turnover Markers**

Since the 2014 AAOMS position paper, there has been a shift away from bone turnover markers. No biomarkers are validated for clinical decision-making, and continued research and prospective studies are required before these markers can be considered efficacious tools in estimating MRONJ risk.

## **Other Biomarkers**

Biomarkers related to angiogenesis, VEGF activity, endocrine function and PTH have more recently been described.<sup>203, 204, 205</sup> These markers remain at an exploratory stage and are not yet validated for clinical decision-making.

## **Prevention Strategies**

### **Patients scheduled to initiate antiresorptive treatment for cancer therapy**

The treatment objective for this group of patients is to minimize the risk of developing MRONJ (Table 2). Although a small percentage of patients receiving antiresorptives develop osteonecrosis of the jaw spontaneously, the majority of affected patients experience this complication following dentoalveolar surgery.<sup>5,112,165,206,207</sup> Therefore, if systemic conditions permit, initiation of antiresorptive therapy should be delayed until dental health is optimized.<sup>173,208</sup> This decision must be made in conjunction with the treating physician and dentist and other specialists involved in the care of the patient. There is widespread consensus that optimizing dental health prior to initiating therapy is efficacious and of paramount importance.<sup>38,185,186,209</sup> Medical oncologists should educate their patients about the importance of dental health and the efficacy of prophylactic dental treatment in the prevention of MRONJ. Similar to patients

who are to receive radiation therapy, optimizing the dental health in patients receiving antiresorptives or other therapies that can compromise bone healing is essential. The pretreatment evaluation of dental health must extend beyond a review of systems and include a physical and radiographic exam. Therefore, a comprehensive dental examination performed by a dental health professional would be a prudent approach for all patients prior to receiving antiresorptive therapy for malignant disease. This level of dental health assessment is most appropriately performed by a dental health professional.

The importance of minimizing the burden of dental infection and inflammation prior to dentoalveolar surgery in this cohort of patients with an elevated MRONJ risk cannot be over-emphasized. Nonrestorable teeth and those with a poor prognosis should be extracted. Other necessary elective dentoalveolar surgery also should be completed at this time. It remains advisable that antiresorptive therapy should be delayed, if systemic conditions permit, until the surgical site(s) have mucosalized or until there is adequate osseous healing. Dental prophylaxis, caries control, conservative restorative dentistry and nonoperative endodontic therapy are critical to maintaining functionally sound teeth. This level of care must be continued on a frequent and indefinite basis.<sup>185</sup>

The posterior lingual plate region is a common site for trauma and mucosal irritation in denture wearers.<sup>5,75,170</sup> Therefore, patients with full or partial dentures should be examined for areas of mucosal trauma, especially along the lingual flange region. It also is critical that patients be educated as to the importance of dental hygiene and regular dental evaluations, and specifically instructed to report any pain, swelling or exposed bone.

### **Patients scheduled to initiate antiresorptive treatment for osteoporosis**

Patients who are scheduled to receive antiresorptive therapy for the prevention of fragility fractures assume a significantly lower risk of MRONJ. Therefore, the urgency and the timing of optimizing the dental health are not as crucial. However, at the initiation of treatment, it would be prudent to educate patients regarding the potential risks

of MRONJ. The importance of optimizing dental health throughout this treatment period and beyond cannot be underestimated.

It is not uncommon for patients to seek the consultation of an oral and maxillofacial surgeon in guiding their decision about starting or continuing antiresorptive therapy. In this scenario, the consulting oral and maxillofacial surgeon should use this opportunity to place the risks and benefits into the proper perspective. More specifically, patients should be reminded of the benefits associated with antiresorptive therapies in preventing fragility fractures and an acknowledgment of the rare occurrence of MRONJ.

The initial enthusiasm and attention associated with the discovery of MRONJ have had unintended consequences. When initially described, a “class effect” was observed, suggesting that MRONJ rates for patients receiving oncologic doses of BPs and those receiving osteoporotic doses of BPs were similar. A plateau and a decline in the use of BPs for osteoporosis was noted in 2006 and is hypothesized to be associated with various safety concerns, such as MRONJ. Patients are becoming increasingly more reluctant to begin or comply with their antiresorptive therapy. Current evidence also confirms an increase in fragility fractures with significant associated morbidity. As one salient example, hip fracture rates in the United States declined each year from 2002 to 2012 and then plateaued at levels higher than projected for 2013 to 2015, attributable to an “osteoporosis treatment gap.”<sup>210</sup> Hip fracture carries significant morbidity, with only 40 percent to 60 percent of individuals recovering their prefracture level of mobility and ability to perform instrumental activities of daily living.<sup>211</sup> These data are representative of a true health crisis. The documented risk for developing MRONJ is low; however, the patient-perceived risk is not. As such, patients are unwilling to start or continue antiresorptive medical therapy. Patients are irrationally denying themselves the tangible therapeutic benefit of antiresorptive therapy to minimize the risk of fragility fractures in order to prevent a minuscule risk of developing MRONJ.

It is clear the benefit of fracture prevention outweighs the risk of MRONJ development in osteoporotic patients.<sup>212</sup> This benefit is even more favorable in the cancer population where bone-stabilizing medications significantly improve quality of life, and it is detrimental when antiresorptives are withheld due to MRONJ safety concerns.

# Position Paper



## **Asymptomatic patients receiving antiresorptive therapies for cancer**

Maintaining good oral hygiene and dental care is of paramount importance in preventing dental disease that may require eventual extractions or other dentoalveolar surgery. Procedures that involve direct osseous injury should be avoided if possible. If a dentoalveolar surgical procedure is unavoidable (e.g., fractured tooth, advanced periodontal disease), patients should be informed of the associated risks. The benefit of a drug holiday remains unsubstantiated in this setting. Nonrestorable teeth may be treated by removal of the crowns and endodontic treatment of the remaining roots.<sup>213</sup> Teeth may be extracted if necessary. Placement of dental implants should be avoided in the oncology patient receiving parenteral antiresorptive therapy or antiangiogenic medications. Case series and systematic reviews have reported necrosis associated with antiresorptive therapy and implant placement.<sup>194, 214, 215, 216</sup>

## **Asymptomatic patients receiving antiresorptive therapy for osteoporosis**

Since the 2014 position paper, epidemiologic data regarding the risk of MRONJ in patients receiving antiresorptive therapy for osteoporosis remain limited due to the lack of sound prospective studies with sufficient power. Nevertheless, the risk for developing MRONJ is between 0.02 percent and 0.04 percent for BPs and 0.3 percent for DMB. (see Table 1). Sound recommendations based on strong clinical research design are still lacking for patients taking oral BPs.

In general, elective dentoalveolar surgery does not appear to be contraindicated in this group. Risk assessment for the development of MRONJ in these patients includes the above-stated data and the discussion above related to drug holidays.

The placement of dental implants in the context of antiresorptive therapy for osteoporosis continues to be an area of research interest. Several systematic reviews have acknowledged the lack of quality data and randomized clinical trials. Some studies have recommended caution,



especially with a longer duration of therapy or steroid use.<sup>194,216</sup> For example, in their systematic review, Granate et al.,<sup>216</sup> identified several studies that reported an elevated MRONJ risk associated with implants placed in the posterior jaw if the duration of bisphosphonate therapy exceeded three years and if the patients were receiving systemic corticosteroids. In contrast to these studies, systematic reviews by Gelazius et al., and Stavropoulos et al., reported no increase in risk.<sup>214,217</sup> A recent retrospective propensity-matched cohort study of 44,900 patients reported a decreased risk of ONJ in osteoporosis patients receiving implants compared to matched controls who did not have implants. Of note, 9,738 patients had a history of BP use, and the results for implants was in contrast to risk increase for patients who underwent tooth extraction.<sup>218</sup>

Reports of implant-related (MRONJ) necrosis can be divided into the early (implant surgery-triggered) or late (implant presence-triggered) category.<sup>215,219,220</sup> In these reviews, the majority of the implant-related necrosis were not related to the initial implant surgery but occurred late (>12 months) and often at sites where implants were placed prior to the initiation of bisphosphonate therapy. The common presentation was an en bloc failure, where the osseointegration of the implants is maintained within the sequestrum.<sup>220,221</sup> This has been recognized as a separate pattern of failure that is distinct from the common peri-implantitis failure and considered by some to be pathognomonic of MRONJ. Although there are no prospective studies or systematic reviews pertaining to implant-related necrosis associated with RANKL inhibitors or other targeted therapies, AAOMS considers this to have a similar level of risk.

In summary, robust data do not exist, and available data are conflicting. Therefore, AAOMS suggests that if dental implants are placed, informed consent should be provided to include the low risk of MRONJ, as well as early and late implant failure. These patients should be placed on a regular long-term recall schedule.

## Treatment Strategies

AAOMS has developed a series of treatment algorithms to streamline the evaluation (Figure 1) and management strategies (Figure 2, Figure 3, Figure 4) for patients with MRONJ. These strategies are based on a current review of nonoperative and operative therapies and their associated outcomes. Emphasis is placed on both nonoperative and operative management being acceptable for all stages of disease based on surgical judgment and patient factors in a shared decision-making model.

## Nonoperative therapy

The efficacy of nonoperative therapies in the management of MRONJ is documented in the literature and provides a useful adjunct to the spectrum of management strategies that also include operative treatment (Figure 2). Nonoperative strategies can be useful in all stages, especially where significant comorbidities preclude operative treatment. They may also result in stabilization of disease or cure in earlier stages. The goal of both operative and nonoperative therapies remains the same: curative therapy and quality-of-life improvement. Nonoperative therapy heavily focuses on patient education, reassurance, control of pain and control of secondary infection to allow for sequestration of the exposed, necrotic bone.<sup>3,63</sup>

Decisions on operative versus nonoperative therapy should be patient-specific and tailored to individual needs. The risk versus benefit ratio (including quality of life with their current symptomology), ability to perform good wound care to prevent infection and disease spread, morbidity from a major surgical procedure, as well as oral function or dental rehabilitation after marginal or segmental resection should be considered. Radiographic imaging is of utmost importance in the evaluation of MRONJ lesions. Three-dimensional imaging can identify forming or fully formed sequestra and potentially decrease the invasiveness of a surgical procedure. Maintenance of maxillary or mandibular integrity is desirable, as the reconstruction of surgical defects in this population can be challenging.<sup>63,222</sup>

Stage 1 patients can be managed with chlorhexidine wound care and improved oral hygiene to remove the biofilm from the necrotic bone surface.<sup>63</sup> Surgery may not be indicated in the absence of disease progression, with patient adequate quality of life.<sup>63, 223</sup> Stage 2 patients may struggle with local wound care and may require antibiotics for symptom control. Those patients who remain refractory to nonoperative treatment or those patients who cannot maintain adequate hygiene may benefit from operative therapy. In the presence of developing or established bony sequestra, nonoperative therapy may be indicated to allow for ultimate sequestrectomy. Exfoliation of the exposed, necrotic bone will often result in disease resolution.<sup>63,224,225</sup>



Therefore, for those patients with Stage 2 or 3 diseases who are poor surgical candidates, nonoperative therapies may be indicated (Figure 2).

There is little evidence to suggest that the use of adjunctive therapies, such as hyperbaric oxygen or ozone therapy, can lead to MRONJ resolution. Larger studies and controlled trials have yet to demonstrate the efficacy of the aforementioned treatments.<sup>226, 227, 228, 229</sup> Therefore, these therapies should not be recommended as a mainstay of treatment at this time.

The use of vitamin E and pentoxifylline as an adjunct to standard MRONJ therapies have been reported only in case studies. A randomized, prospective, placebo-controlled trial of vitamin E and pentoxifylline is underway and will provide additional information about this treatment modality. Teriparatide, one of the few anabolic agents used for the treatment of osteoporosis, also has shown promise as an adjunct for the treatment of MRONJ in osteoporotic patients.<sup>230</sup>

## Operative therapy

While nonoperative therapy continues to be a treatment option for MRONJ, operative therapy is increasingly reported as a viable option with high success rates for all stages of the disease (Figures 3 and 4). Numerous reports have identified high success rates associated with resection of MRONJ lesions.<sup>231, 232, 233, 234, 235, 236, 237</sup> Importantly, one must consider that MRONJ may progress over time, albeit in an unpredictable manner.<sup>238</sup> Furthermore, adopting a nonoperative approach to MRONJ does not uniformly result in sequestration of the exposed necrotic bone with disease resolution.<sup>239</sup> Thus, operative intervention should be explored and presented as a treatment option in an attempt to reduce the progression of disease with the recognition that early surgical intervention can predict beneficial patient outcomes.<sup>240</sup>

Segmental or marginal resection of the mandible and partial maxillectomy are effective methods to control MRONJ.<sup>231, 232, 233, 234, 235, 236, 237, 238, 241</sup> This approach can be applied to patients with all stages of MRONJ, including Stage 1 disease.<sup>169</sup> These resections require margins beyond the borders of the necrotic bone to an area of vital, bleeding bone. Additional reports have identified success when surgical resection of MRONJ was performed by experienced surgeons.<sup>242, 243</sup> Consistent with surgical principles, control of comorbid conditions is paramount in managing MRONJ.<sup>241</sup> Physiologically compromised patients, such as those with an increasing burden of distant metastatic disease, may not respond favorably to

resection of their osteonecrotic jaw and may occasionally develop refractory disease.<sup>241</sup> Finally, surgical resection for MRONJ in patients with metastatic cancer may identify metastases in the jaw specimen, albeit in a minority of patients.<sup>62</sup>

Active clinical and radiographic surveillance is critical in the nonoperative management of patients with Stage 1, 2 and 3 diseases to monitor for signs of disease progression. In patients who demonstrate the failure of nonoperative therapy, early operative intervention is recommended. In patients with a progressive clinical or radiographic disease or more advanced disease at presentation, surgical resection of MRONJ should be performed without first instituting prolonged nonoperative measures. MRONJ represents a complex wound whereby operative therapy can be performed in a timely fashion.<sup>241, 244</sup> Although controversy between operative and nonoperative therapies exist, operative treatment of patients has demonstrated maintenance of mucosal coverage, improved quality of life and expedient resumption of antiresorptive therapy for all stages of MRONJ disease.<sup>245</sup> The benefit of drug holidays for the operative intervention of MRONJ has not been substantiated.

## Future Research

AAOMS realizes that MRONJ is a complex disease process with a multifactorial etiology for which many questions remain unanswered. Continued preclinical and clinical data are required, especially in the form of prospective studies. Continued research efforts and the outcomes that result should be considered the foundation upon which recommendations are developed that will guide patients and providers. While the data supporting the conclusion that antiresorptives represent genuine risk factors are robust, this is not the case for other classifications of medications (e.g., antiangiogenics, corticosteroids, immune modulators). Published studies have reported a relationship of certain dosing practices (e.g., transition from BPs to DMB) or a synergistic effect between antiresorptive medications and antiangiogenic medication with a risk of MRONJ. These associations, however, are based on case reports and small case series. It also has been hypothesized that the total exposure to an

# Position Paper



antiresorptive medication is a risk factor for developing MRONJ. However, this has been difficult to demonstrate, possibly as a result of not having a good measure of exposure other than years of treatment. Similar to the cancer risk associated with tobacco use (e.g., pack/years), the antiresorptive exposure risk MRONJ may be better defined as a cumulative dose load (e.g., mg equivalent of BP/years of exposure) that would account for risk associated with different medications and dosing schedules over time. Dose-reduction protocols and individualized strategies for antiresorptive therapy in long-term cancer survivors with a metastatic bone disease are being explored. It remains to be determined if these protocols will reduce the risk of MRONJ in this patient cohort.<sup>246</sup> AAOMS acknowledges the challenge of elucidating potential risks associated with non-antiresorptive therapies, alone or in combination with antiresorptive medications, and therefore considers it imperative that research efforts continue in the form of prospective studies.

A review of the current literature also failed to provide sound data in the form of randomized, controlled trials that would establish the effectiveness of biomarkers and drug holidays or validate a risk relationship with genetic markers and MRONJ. Until these relationships are established or refuted, AAOMS considers it prudent to recognize that these factors may play a role in the development and management of MRONJ.



# Position Paper



**Table 1**

**MRONJ Disease Frequency Grouped by Disease Status vs Medication\***

Indications for treatment	Medication					Study design
	Placebo	Zoledronate	Oral BPs	Denosumab	Romosozumab	
<b>Malignancy</b>						
Coleman (2020) <sup>138</sup>	0.2% (2,218)*			5% (2,241)		RCT†
O’Carrigan, et al. (2017) <sup>137</sup>	0.7% (6,788)			0.4% (6,788)		Systematic review
O’Carrigan et al. (2017) <sup>137</sup>	0% (3,060)	1% (3,078)				Systematic review
Macherey, et al. (2017) <sup>136</sup>	0.7% (818)	1.5% (808)				Systematic review
Gnant, et al. (2015) <sup>246</sup>	0% (903)	0% (900)				RCT
Coleman, et al. (2014) <sup>133</sup>	0% (1,679)	1.7% (1,681)				RCT
Valachis, et al. (2013) <sup>132</sup>	0% (3,039)	0.52% (4,774)				Systemic review
Boquete-Castro, et al. (2016) <sup>135</sup>	0.1%	1.14%		1.7%		Systematic review
Coleman (2020) <sup>138</sup>	0.2% (2,218)			5.4% (2,214)		RCT
Gnant, et al. (2015) <sup>134</sup>	0% (1,709)			0% (1,711)		RCT
Raje, et al. (2018) <sup>113</sup>		2.8% (82)		4.1% (850)		RCT
Himmelstein (2017) <sup>140</sup>		1.5% (1,822)				RCT
Henry (2014) <sup>141</sup>		1.1% (786)		0.8% (792)		RCT
Yang, et al. (2019) <sup>247</sup>		2% (8,525)				Systematic review
Peddi, et al. (2013) <sup>142</sup>		1.3% (2,846)		1.8% (2,885)		Systematic review
Ng, et al. (2021) <sup>145</sup>		1.6-4%‡ 3.8-18%§		1.9%‡ 6.9%§		Systematic review
Wang, et al. (2014) <sup>144</sup>		1.4% (1,013)		2% (1,020)		Systematic review

(continued on following page)

# Position Paper



(continued from previous page)

Indications for treatment	Medications					Study design
	Placebo	Zoledronate	Oral BPs	Denosumab	Romosozumab	
<b>Osteoporosis</b>						
Papapoulos, et al. (2012) <sup>26</sup>	0% (3,383)			0.04% (4,549)		RCT
Grbic, et al. (2010) <sup>150</sup>	0.02% (4,945)	0.02% (5,864)				Systematic review
Cosman, et al. (2016) <sup>151</sup>	0% (3,322)					RCT
Saag, et al. (2017) <sup>37</sup>			0.05% (2,047)			RCT
Bone, et al. (2017) <sup>153</sup>				0.3% (2,343) 10-yr f/u		RCT
Hallmer, et al. (2018) <sup>75</sup>			0.043%			Population study (50,000)
<b>Non-malignant bone disease</b>						
Chawla, et al. (2019) <sup>156</sup>				5% (532)		Prospective case series
Rutkowski <sup>155</sup>				0.7% (138)		Retrospective case series

\*Sample size in parentheses

†‡Randomized clinical trial

‡ <2 years of followup

§ >2 years of followup



**Table 2**

**MRONJ Prevention Strategies**

<p><b>Pretherapy (nonmalignant disease)</b></p>	<ul style="list-style-type: none"> <li>• Educate patient about the potential risks associated with long-term ART.*</li> <li>• Optimization of dental health can occur concurrent with ART.</li> </ul>
<p><b>Pretherapy (malignant disease)</b></p>	<ul style="list-style-type: none"> <li>• Educate patients about the higher risk of MRONJ and the importance of regimented dental care.</li> <li>• Optimization of the dental health prior to the initiation of ART if systemic conditions permit (extraction of nonrestorable teeth or teeth with a poor prognosis).</li> </ul>
<p><b>During antiresorptive therapy (nonmalignant disease)</b></p>	<ul style="list-style-type: none"> <li>• No alteration of operative plan for most patients.</li> <li>• Considerations include drug schedule, duration of therapy, comorbidities, other medications (especially chemotherapy, steroids or antiangiogenics), degree of underlying infection/inflammation and extent of surgery to be performed. Drug holidays are controversial.</li> <li>• BTM† are not a useful tool to assess MRONJ risk.</li> </ul>
<p><b>During antiresorptive therapy/targeted therapies (malignant disease)</b></p>	<ul style="list-style-type: none"> <li>• Educate patients about the higher MRONJ risk in the setting of malignant disease.</li> <li>• Educate the patient about the importance of regimented dental care and prevention.</li> <li>• Avoid dentoalveolar surgery if possible.</li> <li>• Consider root retention techniques to avoid extractions.</li> <li>• Dental implants are contraindicated.</li> <li>• Drug holidays are controversial.</li> </ul>

\*Antiresorptive therapies

† Bone turnover markers (CTX)



Figure 1

## INITIAL EVALUATION

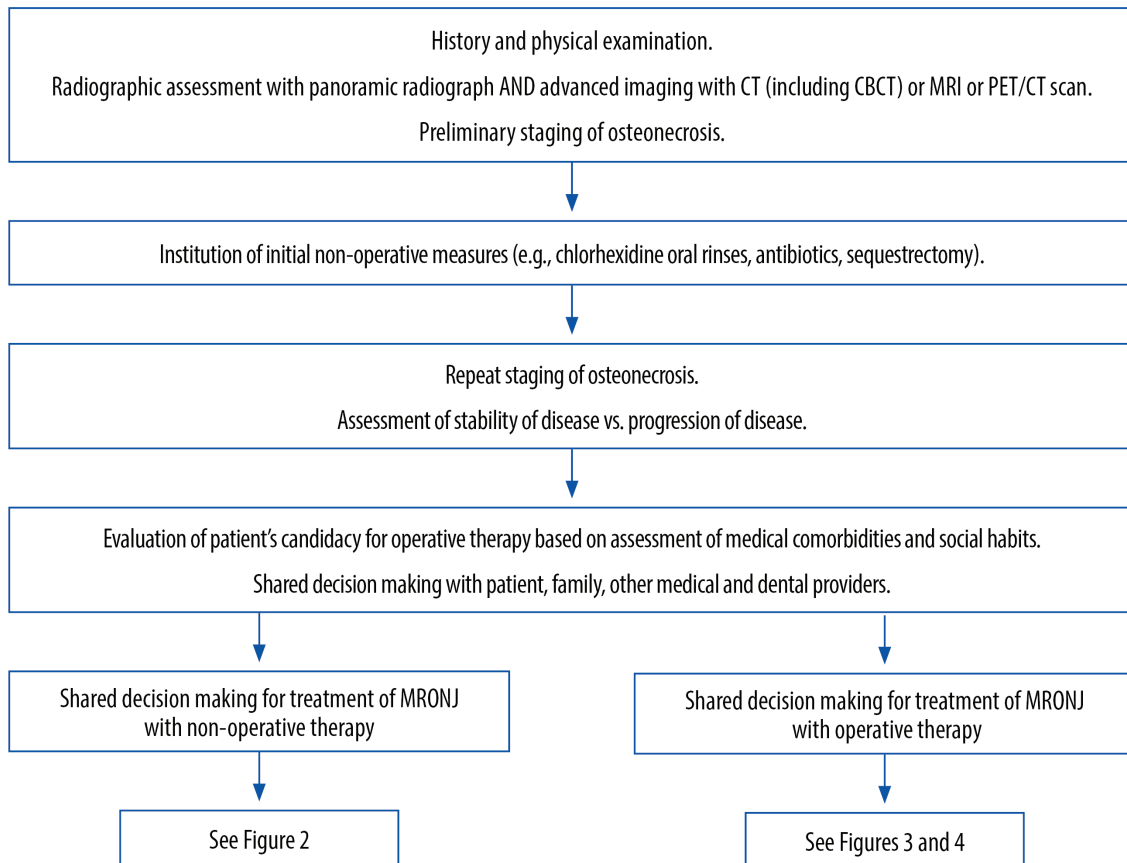




Figure 2

## NON-OPERATIVE THERAPIES

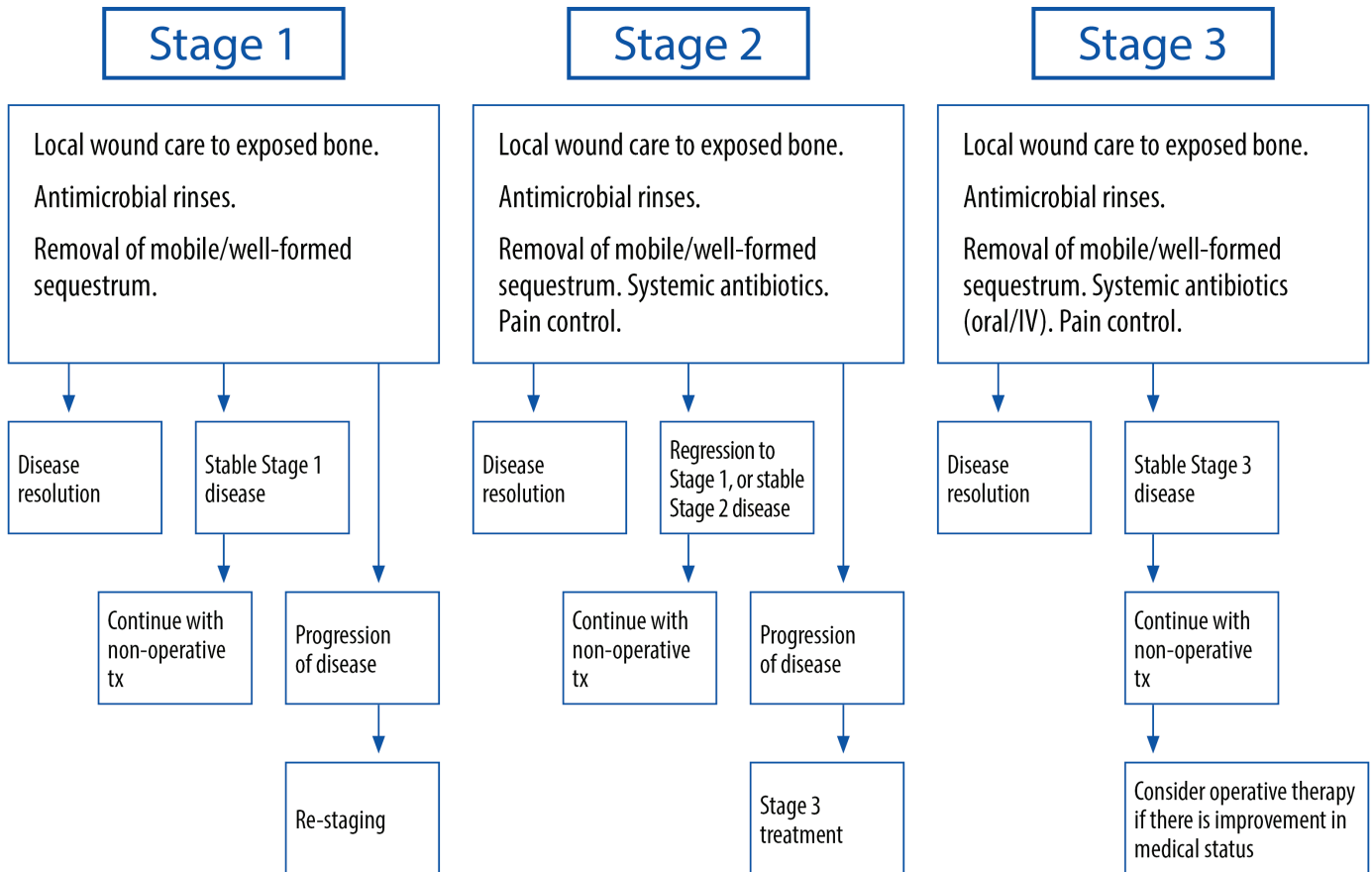




Figure 3

## OPERATIVE THERAPIES FOR MANDIBULAR DISEASE

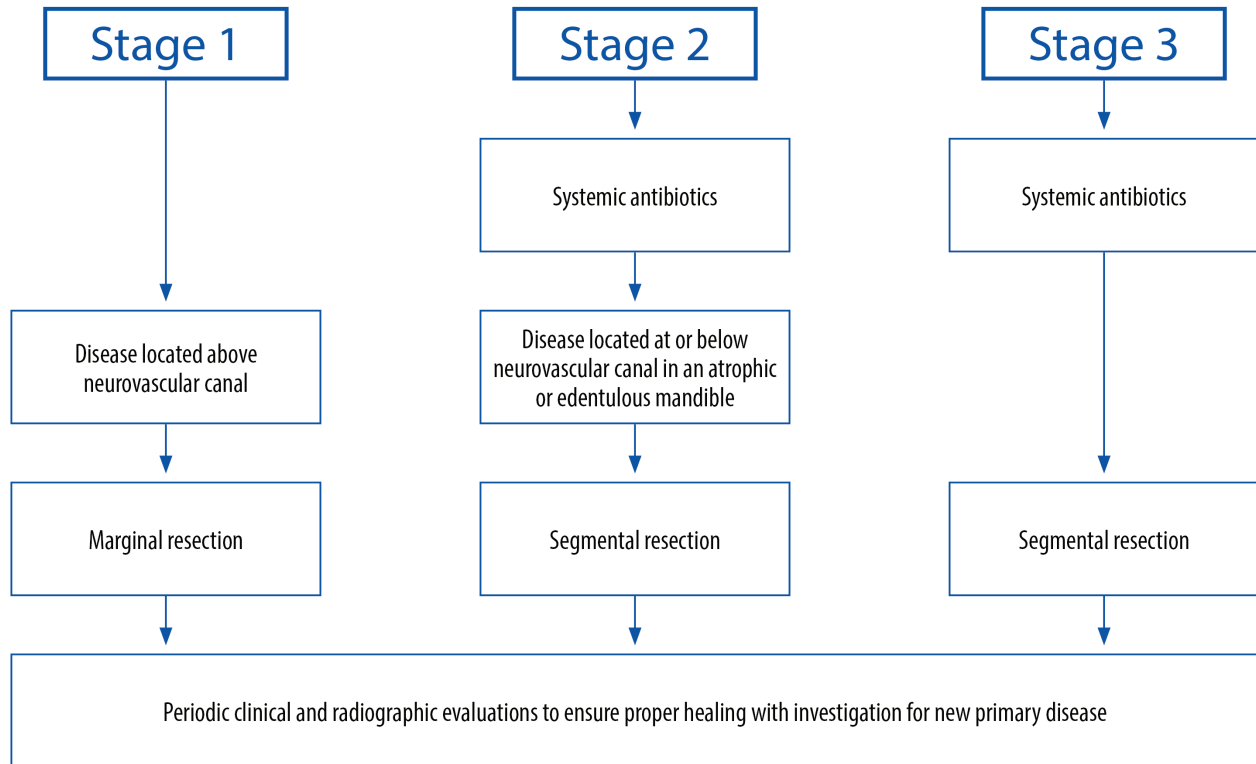
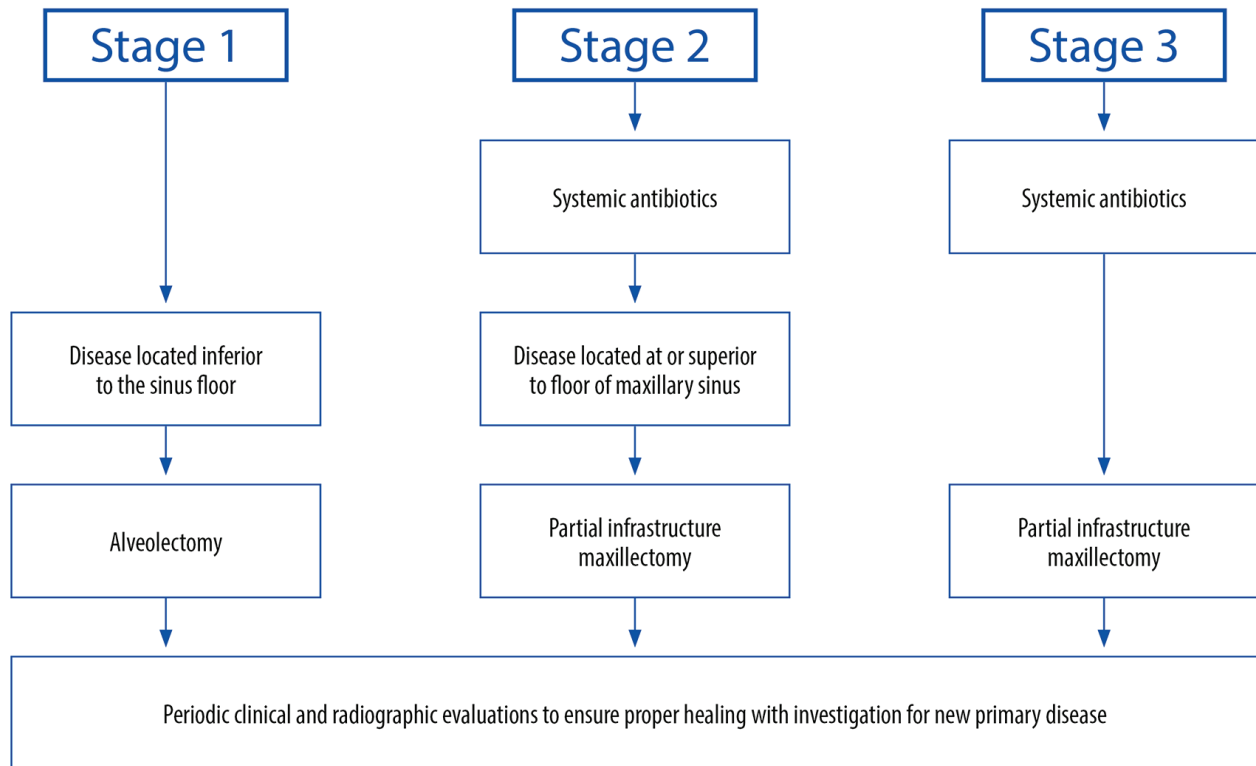




Figure 4

## OPERATIVE THERAPIES FOR MAXILLARY DISEASE



1. American Association of Oral and Maxillofacial Surgeons position paper on bisphosphonate-related osteonecrosis of the jaws. *J Oral Maxillofac Surg.* 65:369, 2007.
2. Ruggiero SL, Dodson TB, Assael LA, et al. American Association of Oral and Maxillofacial Surgeons position paper on bisphosphonate-related osteonecrosis of the jaw - 2009 update. *J Oral Maxillofac Surg.* 67, 2009, Supp 1.
3. Ruggiero SL, Dodson TB, Fantasia J, et al: American Association of Oral and Maxillofacial Surgeons position paper on medication-related osteonecrosis of the jaw—2014 update. *J Oral Maxillofac Surg.* 72:1938, 2014.
4. Saad F, Gleason DM, Murray R, et al: Zoledronic acid prostate cancer study G. A randomized, placebo-controlled trial of zoledronic acid in patients with hormone-refractory metastatic prostate carcinoma. *J Natl Cancer Inst.* 94:1458, 2002.
5. Saad F, Brown JE, Van Poznak C, et al. Incidence, risk factors, and outcomes of osteonecrosis of the jaw: Integrated analysis from three blinded active-controlled phase III trials in cancer patients with bone metastases. *Ann Oncol.* 23:1341, 2012.
6. Rosen LS, Gordon D, Tchekmedyian S, et al. Zoledronic acid versus placebo in the treatment of skeletal metastases in patients with lung cancer and other solid tumors: A phase III, double-blind, randomized trial—the zoledronic acid lung cancer and other solid tumors study group. *J Clin Oncol.* 21:3150, 2003.
7. Hortobagyi GN, Theriault RL, Porter L, et al. Efficacy of pamidronate in reducing skeletal complications in patients with breast cancer and lytic bone metastases. Protocol 19 Aredia Breast Cancer Study Group. *N Engl J Med.* 335:1785, 1996.
8. Hortobagyi GN, Theriault RL, Lipton A, et al. Long-term prevention of skeletal complications of metastatic breast cancer with pamidronate. Protocol 19 Aredia Breast Cancer Study Group. *J Clin Oncol.* 16:2038, 1998.
9. Berenson JR, Lichtenstein A, Porter L, et al. Efficacy of pamidronate in reducing skeletal events in patients with advanced multiple myeloma. Myeloma Aredia Study Group. *N Engl J Med.* 334:488, 1996.
10. Berenson JR, Lichtenstein A, Porter L, et al: Long-term pamidronate treatment of advanced multiple myeloma patients reduces skeletal events. Myeloma Aredia Study Group. *J Clin Oncol.* 16:593, 1998.
11. Berenson JR, Hillner BE, Kyle RA, et al. American Society of Clinical Oncology Bisphosphonates Expert Panel. American Society of Clinical Oncology clinical practice guidelines: The role of bisphosphonates in multiple myeloma. *J Clin Oncol.* 20:3719, 2002.
12. Stopeck A, Brufsky A, Kennedy L, et al. Cost-effectiveness of denosumab for the prevention of skeletal-related events in patients with solid tumors and bone metastases in the United States. *J Med Econ.* 23:37, 2020.
13. Jeon HL, Oh IS, Baek YH, et al. Zoledronic acid and skeletal-related events in patients with bone metastatic cancer or multiple myeloma. *J Bone Miner Metab.* 38:254, 2020.
14. Delmas PD. The use of bisphosphonates in the treatment of osteoporosis. *Curr Opin Rheumatol.* 17:462, 2005.
15. Watts NB. Bisphosphonate treatment of osteoporosis. *Clin Geriatr Med.* 19:395, 2003.
16. Gossiel F, Paggiosi MA, Naylor KE, et al. The effect of bisphosphonates on bone turnover and bone balance in postmenopausal women with osteoporosis: The T-score bone marker approach in the TRIO study. *Bone.* 131:115158, 2020.
17. Black DM, Cummings SR, Karpf DB, et al. Randomized trial of effect of alendronate on risk of fracture in women with existing vertebral fractures. Fracture Intervention Trial Research Group. *Lancet.* 348:1535, 1996.
18. Black DM, Delmas PD, Eastell R, et al. Once-yearly zoledronic acid for treatment of postmenopausal osteoporosis. *N Engl J Med.* 356:1809, 2007.
19. Nakamura T, Fukunaga M, Nakano T, et al. Efficacy and safety of once-yearly zoledronic acid in Japanese patients with primary osteoporosis: Two-year results from a randomized placebo-controlled double-blind study (ZOledroNate treatment in efficacy to osteoporosis; ZONE study). *Osteoporos Int.* 28:389, 2017.
20. Cranney A, Wells G, Willan A, et al. Meta-analyses of therapies for postmenopausal osteoporosis. II. Meta-analysis of alendronate for the treatment of postmenopausal women. *Endocr Rev.* 23:508, 2002.
21. Delmas PD, Meunier PJ. The management of Paget's disease of bone. *N Engl J Med.* 336:558, 1997.
22. Letocha AD, Cintas HL, Troendle JF, et al. Controlled trial of pamidronate in children with types III and IV osteogenesis imperfecta confirms vertebral gains but not short-term functional improvement. *J Bone Miner Res.* 20:977, 2005.
23. Florenzano P, Pan KS, Brown SM, et al. Age-related changes and effects of bisphosphonates on bone turnover and disease progression in fibrous dysplasia of bone. *J Bone Miner Res.* 34:653, 2019.
24. Boyce AM, Kelly MH, Brillante BA, et al. A randomized, double blind, placebo-controlled trial of alendronate treatment for fibrous dysplasia of bone. *J Clin Endocrinol Metab.* 99:4133, 2014.



# Position Paper

25. Cummings SR, San Martin J, McClung MR, et al. Denosumab for prevention of fractures in postmenopausal women with osteoporosis. *N Engl J Med.* 361:756, 2009.
26. Papapoulos S, Chapurlat R, Libanati C, et al. Five years of denosumab exposure in women with postmenopausal osteoporosis: Results from the first two years of the FREEDOM extension. *J Bone Miner Res.* 27:694, 2012.
27. Kanis JA, Harvey NC, Lorentzon M, et al. Combining fracture outcomes in phase 3 trials of osteoporosis: An analysis of the effects of denosumab in postmenopausal women. *Osteoporos Int.* 32:165, 2021.
28. Miller PD, Pannacciulli N, Malouf-Sierra J, et al. Efficacy and safety of denosumab vs. bisphosphonates in postmenopausal women previously treated with oral bisphosphonates. *Osteoporos Int.* 31:181, 2020.
29. Terpos E, Raje N, Croucher P, et al. Denosumab compared with zoledronic acid on PFS in multiple myeloma: Exploratory results of an international phase 3 study. *Blood Adv.* 5:725, 2021.
30. Fizazi K, Carducci M, Smith M, et al. Denosumab versus zoledronic acid for treatment of bone metastases in men with castration-resistant prostate cancer: A randomized, double-blind study. *Lancet.* 377:813, 2011.
31. Stopeck AT, Lipton A, Body JJ, et al. Denosumab compared with zoledronic acid for the treatment of bone metastases in patients with advanced breast cancer: A randomized, double-blind study. *J Clin Oncol.* 28:5132, 2010.
32. Chawla S, Henshaw R, Seeger L, et al. Safety and efficacy of denosumab for adults and skeletally mature adolescents with giant cell tumour of bone: Interim analysis of an open-label, parallel-group, phase 2 study. *Lancet Oncol.* 14:901, 2013.
33. Bredell M, Rordorf T, Kroiss S, et al. Denosumab as a treatment alternative for central giant cell granuloma: A long-term retrospective cohort study. *J Oral Maxillofac Surg.* 76:775, 2018.
34. Boyce AM. Denosumab: An emerging therapy in pediatric bone Disorders. *Curr Osteoporos Rep.* 15:283, 2017.
35. de Castro LF, Burke AB, Wang HD, et al. Activation of RANK/RANKL/OPG pathway is involved in the pathophysiology of fibrous dysplasia and associated with disease burden. *J Bone Miner Res.* 34:290, 2019.
36. Palmisano B, Spica E, Remoli C, et al. RANKL inhibition in fibrous dysplasia of bone: A preclinical study in a mouse model of the human disease. *J Bone Miner Res.* 34:2171, 2019.
37. Saag KG, Petersen J, Brandi ML, et al. Romosozumab or alendronate for fracture prevention in women with osteoporosis. *N Engl J Med.* 377:1417, 2017.
38. Campisi G, Mauceri R, Bertoldo F, et al. Medication-related osteonecrosis of jaws (MRONJ) prevention and diagnosis: Italian consensus update 2020. *Int J Environ Res Public Health.* 17, 2020.
39. Steinberg ME, Hayken GD, Steinberg DR. A quantitative system for staging avascular necrosis. *J Bone Joint Surg Br.* 77:34, 1995.
40. Fleisher KE, Welch G, Kottal S, et al. Predicting risk for bisphosphonate-related osteonecrosis of the jaws: CTX versus radiographic markers. *Oral Surg Oral Med Oral Pathol Oral Radiol Endod.* 110:509, 2010.
41. Fedele S, Porter SR, D’Aiuto F, et al. Nonexposed variant of bisphosphonate-associated osteonecrosis of the jaw: A case series. *Am J Med.* 123:1060, 2010.
42. Fleisher KE, Janal MN, Alstein N, et al. Comorbid conditions are a risk for osteonecrosis of the jaw unrelated to antiresorptive therapy. *Oral Surg Oral Med Oral Pathol Oral Radiol.* 127: 140, 2019.
43. Farah CS, Savage NW. Oral ulceration with bone sequestration. *Aust Dent J.* 48:61, 2003.
44. Filippi A, Dreyer T, Bohle RM, et al. Sequestration of the alveolar bone by invasive aspergillosis in acute myeloid leukemia. *J Oral Pathol Med.* 26:437, 1997.
45. Friel P, Macintyre DR. Bone sequestration from lower 3rd molar region. *Br Dent J.* 193:366, 2002.
46. Huang JS, Kok SH, Lee JJ, et al. Extensive maxillary sequestration resulting from mucormycosis. *Br J Oral Maxillofac Surg.* 43:532, 2005.
47. Peters E, Daley T. American Academy of Oral and Maxillofacial Pathology. Persistent painful ulcer of the posterior lingual mandibular mucosa. *J Contemp Dent Pract.* 4:71, 2003.
48. Sonnier KE, Horning GM. Spontaneous bony exposure: A report of 4 cases of idiopathic exposure and sequestration of alveolar bone. *J Periodontol.* 68:758, 1997.
49. Peters E, Lovas GL, Wysocki GP. Lingual mandibular sequestration and ulceration. *Oral Surg Oral Med Oral Pathol.* 75:739, 1993.
50. Nandakumar H, Shankaramba KB. Massive sequestration of the upper jaw: A case report. *Br J Oral Maxillofac Surg.* 28:55, 1990.
51. Ramon Y, Oberman M, Horowitz I, Freedman. Extensive maxillary sequestration resulting from rhinocerebral mucormycosis. 35:989, 1977.
52. Liao MT, Chien WC, Wang JC, et al. Increased risk of bisphosphonate-related osteonecrosis of the jaw in patients with Sjogren’s syndrome: Nationwide population-based cohort study. *BMJ Open.* 9:e024655, 2019.

# Position Paper

53. Schwartz HC. Osteonecrosis of the jaws. A complication of cancer chemotherapy. *Head Neck Surg.* 4:251, 1982.
54. Cooper JC. Tooth exfoliation and osteonecrosis of the jaw following herpes zoster. *Br Dent J.* 143:297, 1977.
55. Schwartz O, Kvorning SA. Tooth exfoliation, osteonecrosis of the jaw and neuralgia following herpes zoster of the trigeminal nerve. *Int J Oral Surg.* 11:364, 1982.
56. Calhoun KH, Shapiro RD, Stienberg CM, et al. Osteomyelitis of the mandible. *Arch Otolaryngol Head Neck Surg.* 114:1157, 1988.
57. Koerbusch GF, Fotos P, Goll KT. Retrospective assessment of osteomyelitis. Etiology, demographics, risk factors, and management in 35 cases. *Oral Surg Oral Med Oral Pathol.* 74:149, 1992.
58. Maines E, Monti E, Doro F, et al. Children and adolescents treated with neridronate for osteogenesis imperfecta show no evidence of any osteonecrosis of the jaw. *J Bone Miner Metab.* 30:434, 2012.
59. Black DM, Schwartz AV, Ensrud KE, et al. Effects of continuing or stopping alendronate after 5 years of treatment: The fracture intervention trial long-term extension (FLEX): A randomized trial. *JAMA.* 296:2927, 2006.
60. Black DM, Reid IR, Boonen S, et al. The effect of 3 versus 6 years of zoledronic acid treatment of osteoporosis: A randomized extension to the HORIZON-Pivotal fracture trial (PFT). *J Bone Miner Res.* 27:243, 2012.
61. Black DM, Reid IR, Cauley JA, et al. The effect of 6 versus 9 years of zoledronic acid treatment in osteoporosis: A randomized second extension to the HORIZON-Pivotal fracture trial (PFT). *J Bone Miner Res.* 30:934, 2015.
62. Carlson ER, Fleisher KE, Ruggiero SL. Metastatic cancer identified in osteonecrosis specimens of the jaws in patients receiving intravenous bisphosphonate medications. *J Oral Maxillofac Surg.* 71:2077, 2013.
63. Hadaya D, Soundia A, Freymiller E, et al. Nonsurgical management of medication-related osteonecrosis of the jaws using local wound care. *J Oral Maxillofac Surg.* 76:2332, 2018.
64. Marx RE, Sawatari Y, Fortin M, Broumand V. Bisphosphonate-induced exposed bone (osteonecrosis/osteopetrosis) of the jaws: Risk factors, recognition, prevention, and treatment. *J Oral Maxillofac Surg.* 63:1567, 2005.
65. Aghaloo T, Hazboun R, Tetradis S. Pathophysiology of osteonecrosis of the jaws. *Oral Maxillofac Surg Clin North Am.* 27:489, 2015.
66. Johnston CB, Dagar M. Osteoporosis in older adults. *Med Clin North Am* 104:873, 2020.
67. Black DM, Rosen CJ. Clinical practice. Postmenopausal Osteoporosis. *N Engl J Med.* 374:254, 2016.
68. Schwartz E, Reichert Z, Van Poznak C. Pharmacologic management of metastatic bone disease. *Bone.* 115735, 2020.
69. Coleman R. Bisphosphonates and breast cancer from cautious palliation to saving lives. *Bone.* 140:115570, 2020.
70. Lacey DL, Boyle WJ, Simonet WS, et al. Bench to bedside: Elucidation of the OPG-RANK-RANKL pathway and the development of denosumab. *Nat Rev Drug Discov.* 11:401, 2012.
71. Coleman RE, Major P, Lipton A, et al. Predictive value of bone resorption and formation markers in cancer patients with bone metastases receiving the bisphosphonate zoledronic acid. *J Clin Oncol.* 23:4925, 2005.
72. Stewart AF. Clinical practice. Hypercalcemia associated with cancer. *N Engl J Med.* 352:373, 2005.
73. Benjamin B, Benjamin MA, Swe M, Sugathan S. Review on the comparison of effectiveness between denosumab and bisphosphonates in post-menopausal osteoporosis. *Osteoporos Sarcopenia.* 2:77, 2016.
74. Limones A, Saez-Alcaide LM, Diaz-Parreno SA, et al. Medication-related osteonecrosis of the jaws (MRONJ) in cancer patients treated with denosumab vs.. zoledronic acid: A systematic review and meta-analysis. *Med Oral Patol Oral Cir Bucal.* 25: e326, 2020.
75. Hallmer F, Andersson G, Gotrick B, et al. Prevalence, initiating factor, and treatment outcome of medication-related osteonecrosis of the jaw-a 4-year prospective study. *Oral Surg Oral Med Oral Pathol Oral Radiol.* 126:477, 2018.
76. Soundia A, Hadaya D, Esfandi N, et al. Osteonecrosis of the jaws (ONJ) in mice after extraction of teeth with periradicular disease. *Bone.* 90:133, 2016.
77. Wehrhan F, Gross C, Creutzburg K, et al. Osteoclastic expression of higher-level regulators NFATc1 and BCL6 in medication-related osteonecrosis of the jaw secondary to bisphosphonate therapy: A comparison with osteoradionecrosis and osteomyelitis. *J Transl Med.* 17:69, 2019.
78. de Molon RS, Shimamoto H, Bezouglaia O, et al. OPG-Fc but not zoledronic acid discontinuation reverses osteonecrosis of the jaws (ONJ) in mice. *J Bone Miner Res.* 30:1627, 2015.
79. Hadaya D, Soundia A, Gkouveris I, et al. Antiresorptive-type and discontinuation-timing Affect ONJ burden. *J Dent Res.* 100:746, 2021.

# Position Paper

80. Kuroshima S, Entezami P, McCauley LK, Yamashita J. Early effects of parathyroid hormone on bisphosphonate/steroid-associated compromised osseous wound healing. *Osteoporosis Int.* 25:1141, 2014.
81. Dayisoğlu EH, Senel FC, Ungor C, et al. The effects of adjunctive parathyroid hormone injection on bisphosphonate-related osteonecrosis of the jaws: An animal study. *Int J Oral Maxillofac Surg.* 42:1475, 2013.
82. Chopra K, Malhan N. Teriparatide for the treatment of medication-related osteonecrosis of the jaw. *Am J Ther.* 28: e469, 2021.
83. Ficarra G, Beninati F, Rubino I, et al. Osteonecrosis of the jaws in periodontal patients with a history of bisphosphonates treatment. *J Clin Periodontol.* 32:1123, 2005.
84. Thumbigere-Math V, Michalowicz BS, Hodges JS, et al. Periodontal disease as a risk factor for bisphosphonate-related osteonecrosis of the jaw. *J Periodontol.* 85:226, 2014.
85. Aghaloo TL, Kang B, Sung EC, et al. Periodontal disease and bisphosphonates induce osteonecrosis of the jaws in the rat. *J Bone Miner Res.* 26:1871, 2011.
86. Kang B, Cheong S, Chaichanasakul T, et al. Periapical disease and bisphosphonates induce osteonecrosis of the jaws in mice. *J Bone Miner Res.* 28:1631, 2013.
87. Hadaya D, Soundia A, Gkouveris I, et al. Development of medication-related osteonecrosis of the jaw after extraction of teeth with experimental periapical disease. *J Oral Maxillofac Surg.* 77:71, 2019.
88. Aguirre JI, Akhter MP, Kimmel DB, et al. Oncologic doses of zoledronic acid induce osteonecrosis of the jaw-like lesions in rice rats (*Oryzomys palustris*) with periodontitis. *J Bone Miner Res.* 27:2130, 2012.
89. Soma T, Iwasaki R, Sato Y, et al. Tooth extraction in mice administered zoledronate increases inflammatory cytokine levels and promotes osteonecrosis of the jaw. *J Bone Miner Metab.* 39:372, 2021.
90. de Molon RS, Hsu C, Bezouglaia O, et al. Rheumatoid arthritis Exacerbates the severity of osteonecrosis of the jaws (ONJ) in mice. A randomized, prospective, controlled animal study. *J Bone Miner Res.* 31:1596, 2016.
91. Kim T, Kim S, Song M, et al. Removal of pre-existing periodontal inflammatory condition before tooth extraction Ameliorates medication-related osteonecrosis of the jaw-like lesion in mice. *Am J Pathol.* 188:2318, 2018.
92. Kuroshima S, Nakajima K, Sasaki M, et al. Systemic administration of quality and quantity-controlled PBMCs reduces bisphosphonate-related osteonecrosis of jaw-like lesions in mice. *Stem Cell Res Ther.* 10:209, 2019.
93. Hansen T, Kunkel M, Weber A, James Kirkpatrick C. Osteonecrosis of the jaws in patients treated with bisphosphonates histomorphologic analysis in comparison with infected osteoradionecrosis. *J Oral Pathol Med.* 35:155, 2006.
94. Mawardi H, Giro G, Kajjiya M, et al. A role of oral bacteria in bisphosphonate-induced osteonecrosis of the jaw. *J Dent Res.* 90:1339, 2011.
95. Vandone AM, Donadio M, Mozzati M, et al. Impact of dental care in the prevention of bisphosphonate-associated osteonecrosis of the jaw: A single-center clinical experience. *Ann Oncol.* 23:193, 2012.
96. Sedghizadeh PP, Kumar SK, Gorur A, et al. Microbial biofilms in osteomyelitis of the jaw and osteonecrosis of the jaw secondary to bisphosphonate therapy. *J Am Dent Assoc.* 140:1259, 2009.
97. Francini F, Pascucci A, Francini E, et al. Osteonecrosis of the jaw in patients with cancer who received zoledronic acid and bevacizumab. *J Am Dent Assoc.* 142:506, 2011.
98. Migliorati CA, Schubert MM, Peterson DE, Seneda LM. Bisphosphonate-associated osteonecrosis of mandibular and maxillary bone: An emerging oral complication of supportive cancer therapy. *Cancer.* 104:83, 2005.
99. Petek D, Hannouche D, Suva D. Osteonecrosis of the femoral head: Pathophysiology and current concepts of treatment. *EFORT Open Rev.* 4:85, 2019.
100. Wood J, Bonjean K, Ruetz S, et al. Novel antiangiogenic effects of the bisphosphonate compound zoledronic acid. *J Pharmacol Exp Ther.* 302:1055, 2002.
101. Santini D, Vincenzi B, Dicuonzo G, et al. Zoledronic acid induces significant and long-lasting modifications of circulating angiogenic factors in cancer patients. *Clin Cancer Res.* 9: 2893, 2003.
102. Ishtiaq S, Edwards S, Sankaralingam A, et al. The effect of nitrogen containing bisphosphonates, zoledronate and alendronate, on the production of pro-angiogenic factors by osteoblastic cells. *Cytokine.* 71:154, 2015.
103. Kun-Darbois JD, Libouban H, Mabilieu G, et al.: Bone mineralization and vascularization in bisphosphonate-related osteonecrosis of the jaw: An experimental study in the rat. *Clin Oral Investig.* 22:2997, 2018.
104. Gao SY, Lin RB, Huang SH, et al. PDGF-BB exhibited therapeutic effects on rat model of bisphosphonate-related osteonecrosis of the jaw by enhancing angiogenesis and osteogenesis. *Bone.* 144:115117, 2021.
105. Bi Y, Gao Y, Ehrchiou D, et al. Bisphosphonates cause osteonecrosis of the jaw-like disease in mice. *Am J Pathol.* 177:280, 2010.
106. Gkouveris I, Hadaya D, Soundia A, et al.: Vasculature submucosal changes at early stages of osteonecrosis of the jaw (ONJ). *Bone.* 123:234, 2019.

107. Vallina C, Ramirez L, Torres J, et al. Osteonecrosis of the jaws produced by sunitinib: A systematic review. *Med Oral Patol Oral Cir Bucal*. 24:e326, 2019.
108. Gacche RN, Meshram RJ. Angiogenic factors as potential drug target: Efficacy and limitations of anti-angiogenic therapy. *Biochim Biophys Acta*. 1846(1):161, 2014.
109. Akita Y, Kuroshima S, Nakajima K, et al. Effect of anti-angiogenesis induced by chemotherapeutic monotherapy, chemotherapeutic/bisphosphonate combination therapy and anti-VEGFA mAb therapy on tooth extraction socket healing in mice. *J Bone Miner Metab*. 36:547, 2018.
110. Rugani P, Walter C, Kirnbauer B, et al. Prevalence of medication-related osteonecrosis of the jaw in patients with breast cancer, prostate cancer, and multiple myeloma. *Dent J (Basel)*. 4:32, 2016.
111. Dimopoulos MA, Kastritis E, Anagnostopoulos A, et al. Osteonecrosis of the jaw in patients with multiple myeloma treated with bisphosphonates: Evidence of increased risk after treatment with zoledronic acid. *Haematologica*. 91:968, 2006.
112. Badros A, Weikel D, Salama A, et al. Osteonecrosis of the jaw in multiple myeloma patients: Clinical features and risk factors. *J Clin Oncol*. 24:945, 2006.
113. Raje N, Terpos E, Willenbacher W, et al. Denosumab versus zoledronic acid in bone disease treatment of newly diagnosed multiple myeloma: An international, double-blind, double-dummy, randomised, controlled, phase 3 study. *Lancet Oncol*. 19:370, 2018.
114. Lilleul O, Crompot E, Saussez S. Bisphosphonate-induced osteonecrosis of the jaw: A review of 2,400 patient cases. *J Cancer Res Clin Oncol*. 136:1117, 2010.
115. Bastos P, Patel V, Festy F, et al. In-vivo imaging of the microvasculature of the soft tissue margins of osteonecrotic jaw lesions. *Br Dent J*. 223:699, 2017.
116. Zhang Q, Yu W, Lee S, et al. Bisphosphonate induces osteonecrosis of the jaw in diabetic mice via NLRP3/Caspase-1 Dependent IL-1 beta mechanism. *J Bone Miner Res*. 30:2300, 2015.
117. Kabilova TO, Kovtonyuk LV, Zonov EV, et al. Immunotherapy of hepatocellular carcinoma with small double-stranded RNA. *BMC Cancer*. 14:338, 2014.
118. Hayano H, Kuroshima S, Sasaki M, et al. Distinct immunopathology in the early stages between different antiresorptives-related osteonecrosis of the jaw-like lesions in mice. *Bone*. 135:115308, 2020.
119. Rao NJ, Yu RQ, Wang JY, et al. Effect of periapical diseases in development of MRONJ in immunocompromised mouse model. *Biomed Res Int*. 2019:1271492, 2019.
120. Aghaloo TL, Tetradis S. Osteonecrosis of the jaw in the absence of antiresorptive or antiangiogenic exposure: A series of 6 cases. *J Oral Maxillofac Surg*. 75:129, 2017.
121. Bamias A, Kastritis E, Bamia C, et al.: Osteonecrosis of the jaw in cancer after treatment with bisphosphonates: Incidence and risk factors. *J Clin Oncol*. 23:8580, 2005.
122. Qu X, Wang Z, Zhou T, Shan L. Determination of the molecular mechanism by which macrophages and gammadelta-T cells contribute to ZOL-induced ONJ. *Aging (Albany NY)*. 12: 20743, 2020.
123. Rodriguez-Lozano FJ, Onate-Sanchez R, Gonzalez-Garcia M, et al. Allogeneic bone marrow mesenchymal stem cell transplantation in tooth extractions sites Ameliorates the incidence of osteonecrotic jaw-like lesions in zoledronic acid-treated rats. *J Clin Med*. 9:1649, 2020.
124. Alonso-Rodriguez E, Gonzalez-Martin-Moro J, Cebrian-Carretero JL, et al. Bisphosphonate-related osteonecrosis. Application of adipose-derived stem cells in an experimental murine model. *Med Oral Patol Oral Cir Bucal*. 24: e529, 2019.
125. Barba-Recreo P, Del Castillo Pardo de Vera JL, Georgiev-Hristov T, et al. Adipose-derived stem cells and platelet-rich plasma for preventive treatment of bisphosphonate-related osteonecrosis of the jaw in a murine model. *J Craniomaxillofac Surg*. 43:1161, 2015.
126. Sarasquete ME, Garcia-Sanz R, Marin L, et al. Bisphosphonate-related osteonecrosis of the jaw is associated with polymorphisms of the cytochrome P450 CYP2C8 in multiple myeloma: A genome-wide single nucleotide polymorphism analysis. *Blood*. 112:2709, 2008.
127. Yang G, Hamadeh IS, Katz J, et al. SIRT1/HERC4 Locus associated with bisphosphonate-induced osteonecrosis of the jaw: An Exome-wide association analysis. *J Bone Miner Res*. 33:91, 2018.
128. Yang G, Collins JM, Rafiee R, et al. SIRT1 gene SNP rs932658 is associated with medication-related osteonecrosis of the jaw. *J Bone Miner Res*. 36:347, 2021.
129. Lee KH, Kim SH, Kim CH, et al.: Identifying genetic variants underlying medication-induced osteonecrosis of the jaw in cancer and osteoporosis: A case control study. *J Transl Med*. 17: 381, 2019.
130. Kastritis E, Melea P, Bagratuni T, et al.: Genetic factors related with early onset of osteonecrosis of the jaw in patients with multiple myeloma under zoledronic acid therapy. *Leuk Lymphoma*. 58:2304, 2017.
131. Guo Z, Cui W, Que L, et al. Pharmacogenetics of medication-related osteonecrosis of the jaw: A systematic review and meta-analysis. *Int J Oral Maxillofac Surg*. 49:298, 2020.

# Position Paper

132. Valachis A, Polyzos NP, Coleman RE, et al. Adjuvant therapy with zoledronic acid in patients with breast cancer: A systematic review and meta-analysis. *Oncologist*. 18:353, 2013.
133. Coleman R, Cameron D, Dodwell D, et al. Adjuvant zoledronic acid in patients with early breast cancer: Final efficacy analysis of the AZURE (BIG 01/04) randomised open-label phase 3 trial. *Lancet Oncol*. 15:997, 2014.
134. Gnani M, Pfeiler G, Dubsy PC et al. Adjuvant denosumab in breast cancer (ABCSG-18): A multicentre, randomised, double blind, placebo-controlled trial. *Lancet*. 386:433, 2015.
135. Boquete-Castro A, Gomez-Moreno G, Calvo-Guirado JL, et al: Denosumab and osteonecrosis of the jaw. A systematic analysis of events reported in clinical trials. *Clin Oral Implants Res*. 27: 367, 2016.
136. Macherey S, Monsef I, Jahn F, et al. Bisphosphonates for advanced prostate cancer. *Cochrane Database Syst Rev*. 12: CD006250, 2017.
137. O’Carrigan B, Wong MH, Willson ML, et a.: Bisphosphonates and other bone agents for breast cancer. *Cochrane Database Syst Rev*. 10:CD003474, 2017.
138. Coleman R, Finkelstein DM, Barrios C, et al. Adjuvant denosumab in early breast cancer (D-CARE): An international, multicentre, randomised, controlled, phase 3 trial. *Lancet Oncol*. 21:60, 2020.
139. Barrett-Lee P, Casbard A, Abraham J, et al. Oral ibandronic acid versus intravenous zoledronic acid in treatment of bone metastases from breast cancer: A randomised, open label, noninferiority phase 3 trial. *Lancet Oncol*. 15:114, 2014.
140. Himelstein AL, Foster JC, Khatcheressian JL, et al. Effect of longer-Interval vs standard dosing of zoledronic acid on skeletal events in patients with bone metastases: A randomized clinical trial. *JAMA*. 317:48, 2017.
141. Henry D, Vadhan-Raj S, Hirsh V, et al. Delaying skeletal-related events in a randomized phase 3 study of denosumab versus zoledronic acid in patients with advanced cancer: An analysis of data from patients with solid tumors. *Support Care Cancer*. 22: 679, 2014.
142. Peddi P, Lopez-Olivo MA, Pratt GF, Suarez-Almazor ME. Denosumab in patients with cancer and skeletal metastases: A systematic review and meta-analysis. *Cancer Treat Rev*. 39: 97, 2013.
143. Jackson GH, Morgan GJ, Davies FE, et al. Osteonecrosis of the jaw and renal safety in patients with newly diagnosed multiple myeloma: Medical Research Council Myeloma IX Study results. *Br J Haematol*. 166:109, 2014.
144. Wang X, Yang KH, Wanyan P, Tian JH. Comparison of the efficacy and safety of denosumab versus bisphosphonates in breast cancer and bone metastases treatment: A meta-analysis of randomized controlled trials. *Oncol Lett*. 7: 1997, 2014.
145. Ng TL, Tu MM, Ibrahim MFK, et al. Long-term impact of bone-modifying agents for the treatment of bone metastases: A systematic review. *Support Care Cancer*. 29:925, 2021.
146. Fusco V, Santini D, Armento G, et al. Osteonecrosis of jaw beyond antiresorptive (bone-targeted) agents: New horizons in oncology. *Expert Opin Drug Saf*. 15:925, 2016.
147. Nicolatou-Galitis O, Kouri M, Papadopoulou E, et al. Osteonecrosis of the jaw related to non-antiresorptive medications: A systematic review. *Support Care Cancer*. 27:383, 2019.
148. King R, Tanna N, Patel V. Medication-related osteonecrosis of the jaw unrelated to bisphosphonates and denosumab-a review. *Oral Surg Oral Med Oral Pathol Oral Radiol*. 127:289, 2019.
149. Sacco R, Shah S, Leeson R, et al. Osteonecrosis and osteomyelitis of the jaw associated with tumour necrosis factor-alpha (TNF-alpha) inhibitors: A systematic review. *Br J Oral Maxillofac Surg*. 58:25, 2020
150. Grbic JT, Black DM, Lyles KW, et al. The incidence of osteonecrosis of the jaw in patients receiving 5 milligrams of zoledronic acid: Data from the health outcomes and reduced incidence with zoledronic acid once yearly clinical trials program. *J Am Dent Assoc*. 141:1365, 2010..
151. Cosman F, Crittenden DB, Adachi JD, et al. Romosozumab treatment in postmenopausal women with osteoporosis. *N Engl J Med*. 375:1532, 2016.
152. Administration USFaD. Background Document for Meeting of Advisory Committee for Reproductive Health Drugs and Drug Safety and Risk Management Advisory Committee. Adelphi, MD, FDA, HHS, 2011.
153. Bone HG, Wagman RB, Brandi ML, et al. 10 years of denosumab treatment in postmenopausal women with osteoporosis: Results from the phase 3 randomised FREEDOM trial and open-label extension. *Lancet Diabetes Endocrinol*. 5:513, 2017.
154. FDA. Briefing Information for the September 9, 2011 Joint Meeting of the Reproductive Health Drugs Advisory Committee and the Drug Safety and Risk Management Advisory Committee. Adelphi, MD, FDA, HHS, 2011.
155. Rutkowski P, Gaston L, Borkowska A, et al. Denosumab treatment of inoperable or locally advanced giant cell tumor of bone multicenter analysis outside clinical trial. *Eur J Surg Oncol*. 44:1384, 2018.
156. Chawla S, Blay JY, Rutkowski P, et al. Denosumab in patients with giant-cell tumour of bone: A multicentre, open-label, phase 2 study. *Lancet Oncol*. 20:1719, 2019.

# Position Paper

157. Henneidge AA, Jayasinghe J, Khajeh J, Macfarlane TV. Systematic review on the incidence of bisphosphonate related osteonecrosis of the jaw in children diagnosed with osteogenesis imperfecta. *J Oral Maxillofac Res.* 4:e1, 2013.
158. Duarte NT, Rech BO, Martins IG, et al. Can children be affected by bisphosphonate-related osteonecrosis of the jaw? A systematic review. *Int J Oral Maxillofac Surg.* 49:183, 2020.
159. Lo JC, O’Ryan FS, Gordon NP et al. Prevalence of osteonecrosis of the jaw in patients with oral bisphosphonate exposure. *J Oral Maxillofac Surg.* 68: 243, 2010.
160. Aljohani S, Fliefel R, Ihbe J, et al. What is the effect of anti-resorptive drugs (ARDs) on the development of medication-related osteonecrosis of the jaw (MRONJ) in osteoporosis patients: A systematic review. *J Craniomaxillofac Surg.* 45:1493, 2017.
161. Shudo A, Kishimoto H, Takaoka K, Noguchi K. Long-term oral bisphosphonates delay healing after tooth extraction: A single institutional prospective study. *Osteoporos Int.* 29:2315, 2018.
162. Gaudin E, Seidel L, Bacevic M, et al. Occurrence and risk indicators of medication-related osteonecrosis of the jaw after dental extraction: A systematic review and meta-analysis. *J Clin Periodontol.* 42:922, 2015.
163. Watts NB, Grbic JT, Binkley N, et al. Invasive oral procedures and events in postmenopausal women with osteoporosis treated with denosumab for up to 10 Years. *J Clin Endocrinol Metab.* 104:2443, 2019.
164. Mozzati M, Arata V, Gallesio G. Tooth extraction in patients on zoledronic acid therapy. *Oral Oncol.* 48:817, 2012.
165. Yamazaki T, Yamori M, Ishizaki T, et al. Increased incidence of osteonecrosis of the jaw after tooth extraction in patients treated with bisphosphonates: A cohort study. *Int J Oral Maxillofac Surg.* 41:1397, 2012.
166. Scoletta M, Arata V, Arduino PG, et al. Tooth extractions in intravenous bisphosphonate-treated patients: A refined protocol. *J Oral Maxillofac Surg.* 71:994, 2013.
167. Bodem JP, Kargus S, Eckstein S, et al. Incidence of bisphosphonate-related osteonecrosis of the jaw in high-risk patients undergoing surgical tooth extraction. *J Craniomaxillofac Surg.* 43:510, 2015.
168. McGowan K, McGowan T, Ivanovski S. Risk factors for medication-related osteonecrosis of the jaws: A systematic review. *Oral Dis.* 24:527, 2018.
169. Kyrgidis A, Vahtsevanos K, Koloutsos G, et al. Bisphosphonate-related osteonecrosis of the jaws: A case-control study of risk factors in breast cancer patients. *J Clin Oncol.* 26:4634, 2008.
170. Vahtsevanos K, Kyrgidis A, Verrou E, et al. Longitudinal cohort study of risk factors in cancer patients of bisphosphonate-related osteonecrosis of the jaw. *J Clin Oncol.* 27:5356, 2009.
171. Tsao C, Darby I, Ebeling PR, et al. Oral health risk factors for bisphosphonate-associated jaw osteonecrosis. *J Oral Maxillofac Surg.* 71:1360, 2013.
172. Qi WX, Tang LN, He AN, et al. Risk of osteonecrosis of the jaw in cancer patients receiving denosumab: A meta-analysis of seven randomized controlled trials. *Int J Clin Oncol.* 19:403, 2014.
173. Ripamonti CI, Maniczzo M, Campa T, et al. Decreased occurrence of osteonecrosis of the jaw after implementation of dental preventive measures in solid tumour patients with bone metastases treated with bisphosphonates. The experience of the National Cancer Institute of Milan. *Ann Oncol.* 20:137, 2009.
174. Montefusco V, Gay F, Spina F, et al. Antibiotic prophylaxis before dental procedures may reduce the incidence of osteonecrosis of the jaw in patients with multiple myeloma treated with bisphosphonates. *Leuk Lymphoma.* 49:2156, 2008.
175. Bantis A, Zissimopoulos A, Sountoulides P, et al. Bisphosphonate-induced osteonecrosis of the jaw in patients with bone metastatic, hormone-sensitive prostate cancer. Risk factors and prevention strategies. *Tumori.* 97:479, 2011.
176. Kunchur R, Goss AN. The oral health status of patients on oral bisphosphonates for osteoporosis. *Aust Dent J.* 53:354, 2008.
177. Lodi G, Sardella A, Salis A, et al. Tooth extraction in patients taking intravenous bisphosphonates: A preventive protocol and case series. *J Oral Maxillofac Surg.* 68:107, 2010.
178. Mozzati M, Gallesio G, Arata V, et al. Platelet-rich therapies in the treatment of intravenous bisphosphonate-related osteonecrosis of the jaw: A report of 32 cases. *Oral Oncol.* 48:469, 2012.
179. Ferlito S, Puzzo S, Liardo C. Preventive protocol for tooth extractions in patients treated with zoledronate: A case series. *J Oral Maxillofac Surg.* 69:e1, 2011.
180. Schubert M, Klatter I, Linek W, et al. The saxon bisphosphonate register - therapy and prevention of bisphosphonate-related osteonecrosis of the jaws. *Oral Oncol.* 48:349, 2012.
181. Bonacina R, Mariani U, Villa F, Villa A. Preventive strategies and clinical implications for bisphosphonate-related osteonecrosis of the jaw: A review of 282 patients. *J Can Dent Assoc.* 77:b147, 2011.
182. Khan AA, Morrison A, Hanley DA, et al. International Task Force on Osteonecrosis of the Jaw. Diagnosis and management of osteonecrosis of the jaw: a systematic review and international consensus. *J Bone Miner Res.* 30:3, 2015.

183. Japanese Allied Committee on Osteonecrosis of the Jaw, Yoneda T, Hagino H, Sugimoto T, et al. Antiresorptive agent-related osteonecrosis of the jaw: Position paper 2017 of the Japanese Allied Committee on osteonecrosis of the jaw. *J Bone Miner Metab.* 35: 6, 2017.
184. Aparecida Cariolatto F, Carelli J, de Campos Moreira T, et al. Recommendations for the prevention of bisphosphonate-related osteonecrosis of the jaw: A systematic review. *J Evid Based Dent Pract.* 18:142, 2018.
185. Beth-Tasdogan NH, Mayer B, Hussein H, Zolk O. Interventions for managing medication-related osteonecrosis of the jaw. *Cochrane Database Syst Rev.* 10:CD012432, 2017.
186. Mucke T, Deppe H, Hein J, et al. Prevention of bisphosphonate-related osteonecrosis of the jaws in patients with prostate cancer treated with zoledronic acid - a prospective study over 6 years. *J Craniomaxillofac Surg.* 44:1689, 2016.
187. Smidt-Hansen T, Folkmar TB, Fode K, et al. Combination of zoledronic Acid and targeted therapy is active but may induce osteonecrosis of the jaw in patients with metastatic renal cell carcinoma. *J Oral Maxillofac Surg.* 71:1532, 2013.
188. Sivoilella S, Lumachi F, Stellini E, Favero L. Denosumab and anti-angiogenic drug-related osteonecrosis of the jaw: An uncommon but potentially severe disease. *Anticancer Res.* 33:1793, 2013.
189. Patel V, McLeod NM, Rogers SN, Brennan PA. Bisphosphonate osteonecrosis of the jaw—a literature review of UK policies versus international policies on bisphosphonates, risk factors and prevention. *Br J Oral Maxillofac Surg.* 49:251, 2011.
190. Hellstein JW, Adler RA, Edwards B, et al. Ristic H, American Dental Association Council on scientific Affairs Expert Panel on antiresorptive Agents: Managing the care of patients receiving antiresorptive therapy for prevention and treatment of osteoporosis: Executive summary of recommendations from the American Dental Association Council on scientific Affairs. *J Am Dent Assoc.* 142:1243, 2011.
191. Atalay B, Yalcin S, Emes Y, et al. Bisphosphonate-related osteonecrosis: Laser-assisted surgical treatment or conventional surgery? *Lasers Med Sci.* 26:815, 2011.
192. Guarneri V, Miles D, Robert N, et al. Bevacizumab and osteonecrosis of the jaw: Incidence and association with bisphosphonate therapy in three large prospective trials in advanced breast cancer. *Breast Cancer Res Treat.* 122:181, 2010.
193. Edwards BJ, Hellstein JW, Jacobsen PL, et al. American Dental Association Council on scientific Affairs Expert Panel on bisphosphonate-associated osteonecrosis of the Jaw: Updated recommendations for managing the care of patients receiving oral bisphosphonate therapy: An advisory statement from the American Dental Association Council on scientific Affairs. *J Am Dent Assoc.* 139:1674, 2008.
194. de-Freitas NR, Lima LB, de-Moura MB, et al. Bisphosphonate treatment and dental implants: A systematic review. *Med Oral Patol Oral Cir Bucal.* 21:e644, 2016.
195. de Molon RS, Cheong S, Bezouglaia O, et al. Spontaneous osteonecrosis of the jaws in the maxilla of mice on antiresorptive treatment: A novel ONJ mouse model. *Bone.* 68:11, 2014.
196. Messer JG, Jiron JM, Mendieta Calle JL, et al. Zoledronate treatment duration is linked to bisphosphonate-related osteonecrosis of the jaw prevalence in rice rats with generalized periodontitis. *Oral Dis.* 25:1116, 2019.
197. Hinchy NV, Jayaprakash V, Rossitto. RA, et al. Osteonecrosis of the jaw - prevention and treatment strategies for oral health professionals. *Oral Oncol.* 49:878, 2013.
198. Khan AA, Morrison A, Kendler DL, et al. International task Force on osteonecrosis of the Jaw: Case-based review of osteonecrosis of the jaw (ONJ) and application of the international recommendations for management from the international task Force on ONJ. *J Clin Densitom.* 20:8, 2017.
199. Ottesen C, Schiodt M, Gotfredsen K. Efficacy of a high-dose antiresorptive drug holiday to reduce the risk of medication-related osteonecrosis of the jaw (MRONJ): A systematic review. *Heliyon.* 6:e03795, 2020.
200. Anastasilakis AD, Polyzos SA, Makras P, et al. Clinical features of 24 patients with rebound-associated vertebral fractures after denosumab discontinuation: Systematic review and additional cases. *J Bone Miner Res.* 32:1291, 2017.
201. Cummings SR, Ferrari S, Eastell R, et al. Vertebral fractures after discontinuation of denosumab: A post Hoc analysis of the randomized placebo-controlled FREEDOM trial and its extension. *J Bone Miner Res.* 33:190, 2018.
202. Tsourdi E, Langdahl B, Cohen-Solal M, et al. Discontinuation of denosumab therapy for osteoporosis: A systematic review and position statement by ECTS. *Bone.* 105:11, 2017.
203. Lorenzo-Pouso AI, Perez-Sayans M, Gonzalez-Palanca S, et al. Biomarkers to predict the onset of bisphosphonate-related osteonecrosis of the jaw: A systematic review. *Med Oral Patol Oral Cir Bucal.* 24:e26, 2019.
204. Musolino C, Oteri G, Allegra A, et al. Altered microRNA expression profile in the peripheral lymphoid compartment of multiple myeloma patients with bisphosphonate-induced osteonecrosis of the jaw. *Ann Hematol.* 97:1259, 2018.
205. Yang R, Tao Y, Wang C, et al. Circulating microRNA Panel as a novel biomarker to Diagnose bisphosphonate-related osteonecrosis of the jaw. *Int J Med Sci.* 15:1694, 2018.



206. Durie BG, Katz M, Crowley J. Osteonecrosis of the jaw and bisphosphonates. *N Engl J Med.* 353:99, 2005.
207. Hoff AO, Toth BB, Altundag K, et al. Frequency and risk factors associated with osteonecrosis of the jaw in cancer patients treated with intravenous bisphosphonates. *J Bone Miner Res.* 23:826, 2008.
208. Dimopoulos MA, Kastritis E, Bamia C, et al. Reduction of osteonecrosis of the jaw (ONJ) after implementation of preventive measures in patients with multiple myeloma treated with zoledronic acid. *Ann Oncol.* 20:117, 2009.
209. Yarom N, Shapiro CL, Peterson DE, et al. Medication-related osteonecrosis of the jaw: MASCC/ISOO/ASCO clinical practice guideline. *J Clin Oncol.* 37:2270, 2019.
210. Lewiecki EM, Wright NC, Curtis JR, et al. Hip fracture trends in the United States, 2002 to 2015. *Osteoporos Int.* 29:717, 2018.
211. Guzon-Illescas O, Perez Fernandez E, Crespi Villarias N, et al. Mortality after osteoporotic hip fracture: Incidence, trends, and associated factors. *J Orthop Surg Res.* 14:203, 2019.
212. McCauley LK. Clinical recommendations for prevention of secondary fractures in patients with osteoporosis: Implications for dental care. *J Am Dent Assoc.* 151:311, 2020.
213. Moinzadeh AT, Shemesh H, Neirynek NA, et al. Bisphosphonates and their clinical implications in endodontic therapy. *Int Endod J.* 46:391, 2013.
214. Gelazius R, Poskevicius L, Sakavicius D, et al. Dental implant placement in patients on bisphosphonate therapy: A systematic review. *J Oral Maxillofac Res.* 9:e2, 2018.
215. Holzinger D, Seemann R, Matoni N, et al. Effect of dental implants on bisphosphonate-related osteonecrosis of the jaws. *J Oral Maxillofac Surg.* 72:1937.e1, 2014.
216. Granate-Marques A, Polis-Yanes C, Seminario-Amez M, et al. Medication-related osteonecrosis of the jaw associated with implant and regenerative treatments: Systematic review. *Med Oral Patol Oral Cir Bucal.* 24:e195, 2019.
217. Stavropoulos A, Bertl K, Pietschmann P, Pandis N, Schiødt M, Klinge. The effect of antiresorptive drugs on implant therapy: Systematic review and meta-analysis. *B Clin Oral Implants Res.* 2018 Oct;29 Suppl 18:54-92.
218. Ryu JI, Kim HY, Kwon YD. Is implant surgery a risk factor for osteonecrosis of the jaw in older adult patients with osteoporosis? A national cohort propensity score-matched study. *Clin Oral Implants Res.* 32:437, 2021.
219. Giovannacci I, Meleti M, Manfredi M, et al. Medication-related osteonecrosis of the jaw around dental implants: Implant surgery-triggered or implant presence-triggered osteonecrosis? *J Craniofac Surg.* 27:697, 2016.
220. Kwon TG, Lee CO, Park JW, et al. Osteonecrosis associated with dental implants in patients undergoing bisphosphonate treatment. *Clin Oral Implants Res.* 25:632, 2014.
221. Pogrel MA, Ruggiero SL. Previously successful dental implants can fail when patients commence anti-resorptive therapy—a case series. *Int J Oral Maxillofac Surg.* 47:220, 2018.
222. Walton K, Grogan TR, Eshaghzadeh E, et al. Medication related osteonecrosis of the jaw in osteoporotic vs oncologic patients - quantifying radiographic appearance and relationship to clinical findings. *Dentomaxillofac Radiol.* 48:20180128, 2019.
223. Coropciuc RG, Grisar K, Aerden T, et al. Medication-related osteonecrosis of the jaw in oncological patients with skeletal metastases: Conservative treatment is effective up to stage 2. *Br J Oral Maxillofac Surg.* 55:787, 2017.
224. Akrioula Soundia, Danny Hadaya, Sanjay M Mallya, Tara L Aghaloo, Sotirios Tetradis. Radiographic predictors of bone exposure in patients with stage 0 medication-related osteonecrosis of the jaws. *Surg Oral Med Oral Pathol Oral Radiol.* 126(6), 2018.
225. Varoni EM, Lombardi N, Villa G, et al. Conservative management of medication-related osteonecrosis of the jaws (MRONJ): A retrospective cohort study. *Antibiotics (Basel).* 10, 2021.
226. Ripamonti CI, Cislighi E, Mariani L, Maniezzo M. Efficacy and safety of medical ozone (O<sub>3</sub>) delivered in oil suspension applications for the treatment of osteonecrosis of the jaw in patients with bone metastases treated with bisphosphonates: Preliminary results of a phase I-II study. *Oral Oncol.* 47:185, 2011.
227. Freiberger JJ, Padilla-Burgos R, McGraw T, et al. What is the role of hyperbaric oxygen in the management of bisphosphonate-related osteonecrosis of the jaw: A randomized controlled trial of hyperbaric oxygen as an adjunct to surgery and antibiotics. *J Oral Maxillofac Surg.* 70:1573, 2012.
228. Epstein MS, Wicknick FW, Epstein JB, et al. Management of bisphosphonate-associated osteonecrosis: Pentoxifylline and tocopherol in addition to antimicrobial therapy. An initial case series. *Oral Surg Oral Med Oral Pathol Oral Radiol Endod.* 110:593, 2010.
229. Morishita K, Yamada SI, Kawakita A, et al. Treatment outcomes of adjunctive teriparatide therapy for medication-related osteonecrosis of the jaw (MRONJ): A multicenter retrospective analysis in Japan. *J Orthop Sci.* 25:1079, 2020.
230. Sim IW, Borromeo GL, Tsao C, et al. Teriparatide promotes bone healing in medication-related osteonecrosis of the jaw: A placebo-controlled, randomized trial. *J Clin Oncol.* 38:2971, 2020.
231. Carlson ER, Basile JD. The role of surgical resection in the management of bisphosphonate-related osteonecrosis of the jaws. *J Oral Maxillofac Surg.* 67:85, 2009.



232. Abu-Id MH, Warnke PH, Gottschalk J, et al. "Bisphossy jaws" - high and low risk factors for bisphosphonate-induced osteonecrosis of the jaw. *J Craniomaxillofac Surg.* 36:95, 2008.
233. Wutzl A, Biedermann E, Wanschitz F, et al. Treatment results of bisphosphonate-related osteonecrosis of the jaws. *Head Neck.* 30:1224, 2008.
234. Stanton DC, Balasanian E. Outcome of surgical management of bisphosphonate-related osteonecrosis of the jaws: Review of 33 surgical cases. *J Oral Maxillofac Surg.* 67:943, 2009.
235. Wilde F, Heufelder M, Winter K, et al. The role of surgical therapy in the management of intravenous bisphosphonates-related osteonecrosis of the jaw. *Oral Surg Oral Med Oral Pathol Oral Radiol Endod.* 111:153, 2011.
236. Adornato MC, Morcos I, Rozanski J. The treatment of bisphosphonate-associated osteonecrosis of the jaws with bone resection and autologous platelet-derived growth factors. *J Am Dent Assoc.* 138:971, 2007.
237. Williamson R. Surgical management of bisphosphonate induced osteonecrosis of the jaws. *Int J Oral Maxillofac Surg.* 39.:251, 2010.
238. Carlson ER. Management of antiresorptive osteonecrosis of the jaws with primary surgical resection. *J Oral Maxillofac Surg.* 72: 655, 2014.
239. Watters AL, Hansen HJ, Williams T, et al. Intravenous bisphosphonate-related osteonecrosis of the jaw: Long-term follow-up of 109 patients. *Oral Surg Oral Med Oral Pathol Oral Radiol.* 115:192, 2013.
240. Ristow O, Ruckschloss T, Muller M, et al. Is the conservative non-surgical management of medication-related osteonecrosis of the jaw an appropriate treatment option for early stages? A long-term single-center cohort study. *J Craniomaxillofac Surg.* 47:491, 2019.
241. Carlson ER, Schlott BJ: Anti-resorptive osteonecrosis of the jaws. Facts forgotten, questions answered, lessons learned. *Oral Maxillofac Surg Clin North Am.* 26:171, 2014.
242. Klingelhoffer C, Zeman F, Meier J, et al. Evaluation of surgical outcome and influencing risk factors in patients with medication-related osteonecrosis of the jaws. *J Craniomaxillofac Surg.* 44:1694, 2016.
243. Nisi M, La Ferla F, Karapetsa D, et al. Conservative surgical management of patients with bisphosphonate-related osteonecrosis of the jaws: A series of 120 patients. *Br J Oral Maxillofac Surg.* 54:930, 2016
244. Park H, Copeland C, Henry S, Barbul A: Complex wounds and their management. *Surg Clin North Am.* 90:1181, 2010.
245. Giudice A, Barone S, Diodati F, et al: Can surgical management improve resolution of medication-related osteonecrosis of the jaw at early stages? A prospective cohort study. *J Oral Maxillofac Surg.* 78:1986, 2020.
246. Rachner TD, Coleman R, Hadji P, Hofbauer LC: Individualized bone-protective management in long-term cancer survivors with bone metastases. *J Bone Miner Res.* 36:1906, 2021.
247. Gnant M, Mlineritsch B, Stoeger H, et al. Colorectal cancer study group VA: Zoledronic acid combined with adjuvant endocrine therapy of tamoxifen versus anastrozol plus ovarian function suppression in premenopausal early breast cancer: Final analysis of the Austrian breast and Colorectal cancer study group trial 12. *Ann Oncol* 26:313, 2015.
248. Yang YL, Xiang ZJ, Yang JH, et al. The incidence and relative risk of adverse events in patients treated with bisphosphonate therapy for breast cancer: A systematic review and meta-analysis. *Ther Adv Med Oncol.* June 9;11, 2019.

## DISCLAIMER

The American Association of Oral and Maxillofacial Surgeons (AAOMS) is providing this position paper on Medication Related Osteonecrosis of the Jaw (MRONJ) to inform practitioners, patients and other interested parties. The position paper is based on a review of the existing literature and the clinical observations of a Special Committee composed of oral and maxillofacial surgeons, oral pathologists, and oncologists experienced in the diagnosis, surgical and adjunctive treatment of diseases, injuries and defects involving both the functional and esthetic aspects of the hard and soft tissues of the oral and maxillofacial regions, epidemiologists, and basic researchers.

The position paper is informational in nature and is not intended to set any standards of care. AAOMS cautions all readers that the strategies described in the position paper are NOT practice parameters or guidelines and may NOT be suitable for every, or any, purpose or application. This position paper cannot substitute for the individual judgment brought to each clinical situation by the patient's oral and maxillofacial surgeon. As with all clinical materials, the position paper reflects the science related to MRONJ at the time of the paper's development, and it should be used with the clear understanding that continued research and practice may result in new knowledge or recommendations. AAOMS makes no express or implied warranty regarding the accuracy, content, completeness, reliability, operability, or legality of information contained within the position paper, including, without limitation, the warranties of merchantability, fitness for a particular purpose, and non-infringement of proprietary rights. In no event shall the AAOMS be liable to the user of the position paper or anyone else for any decision made or action taken by him or her in reliance on such information.

# Position Paper

